



Pantomografia: anatomia radiologiczna

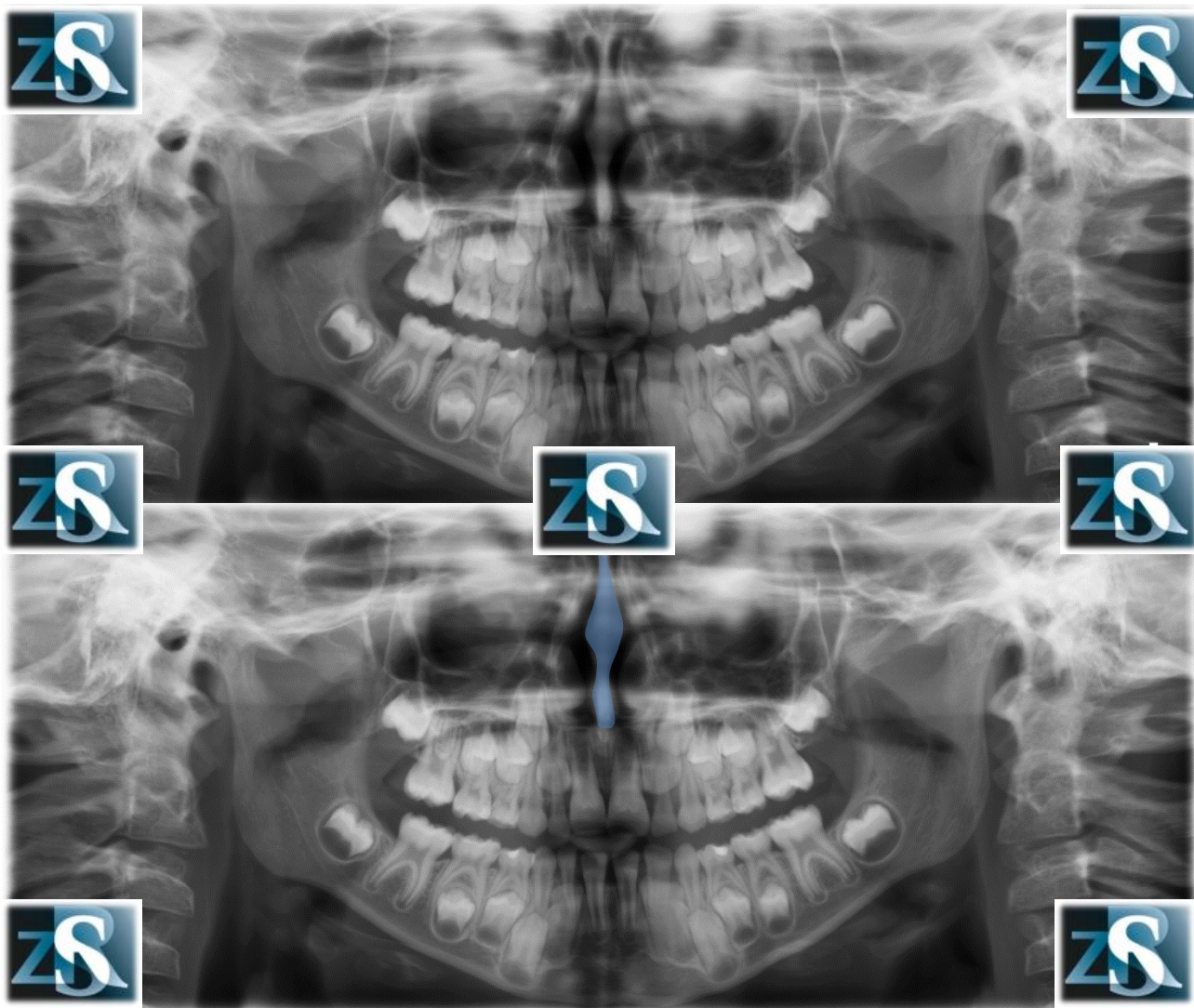
Kazimierz Szopiński

Department of Dental and Maxillofacial Radiology

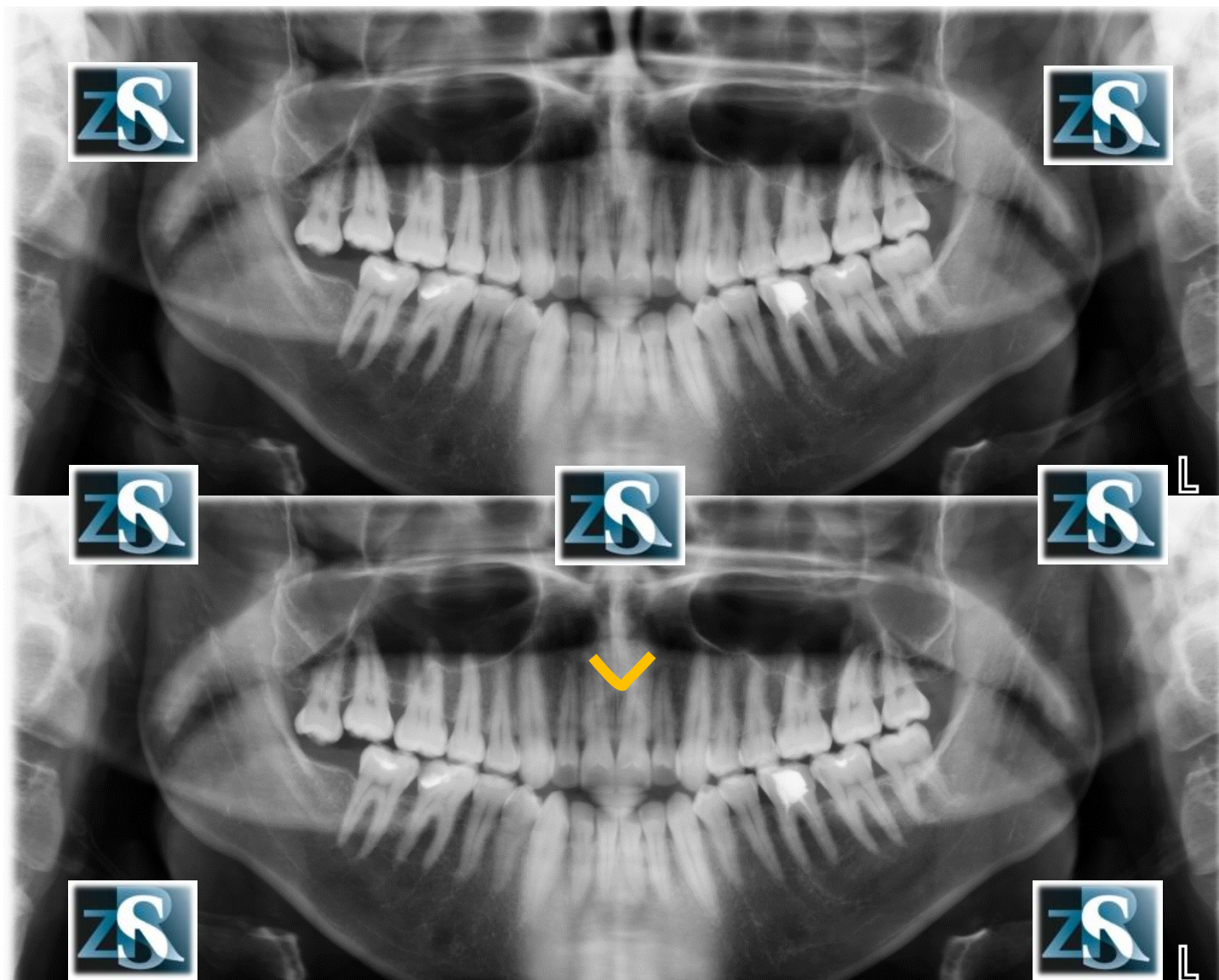
Faculty of Medicine and Dentistry

Medical University of Warsaw

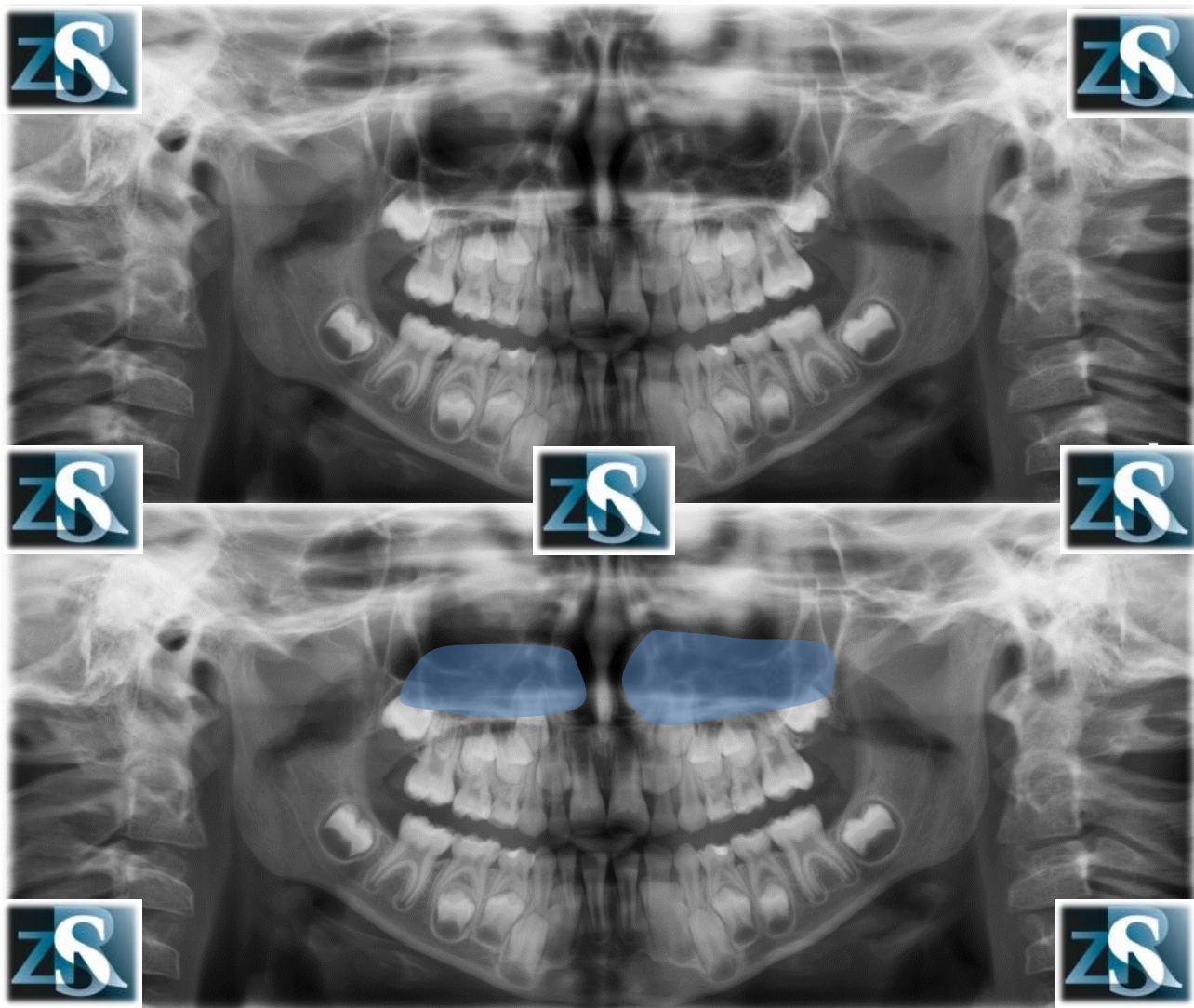
Przegroda nosa



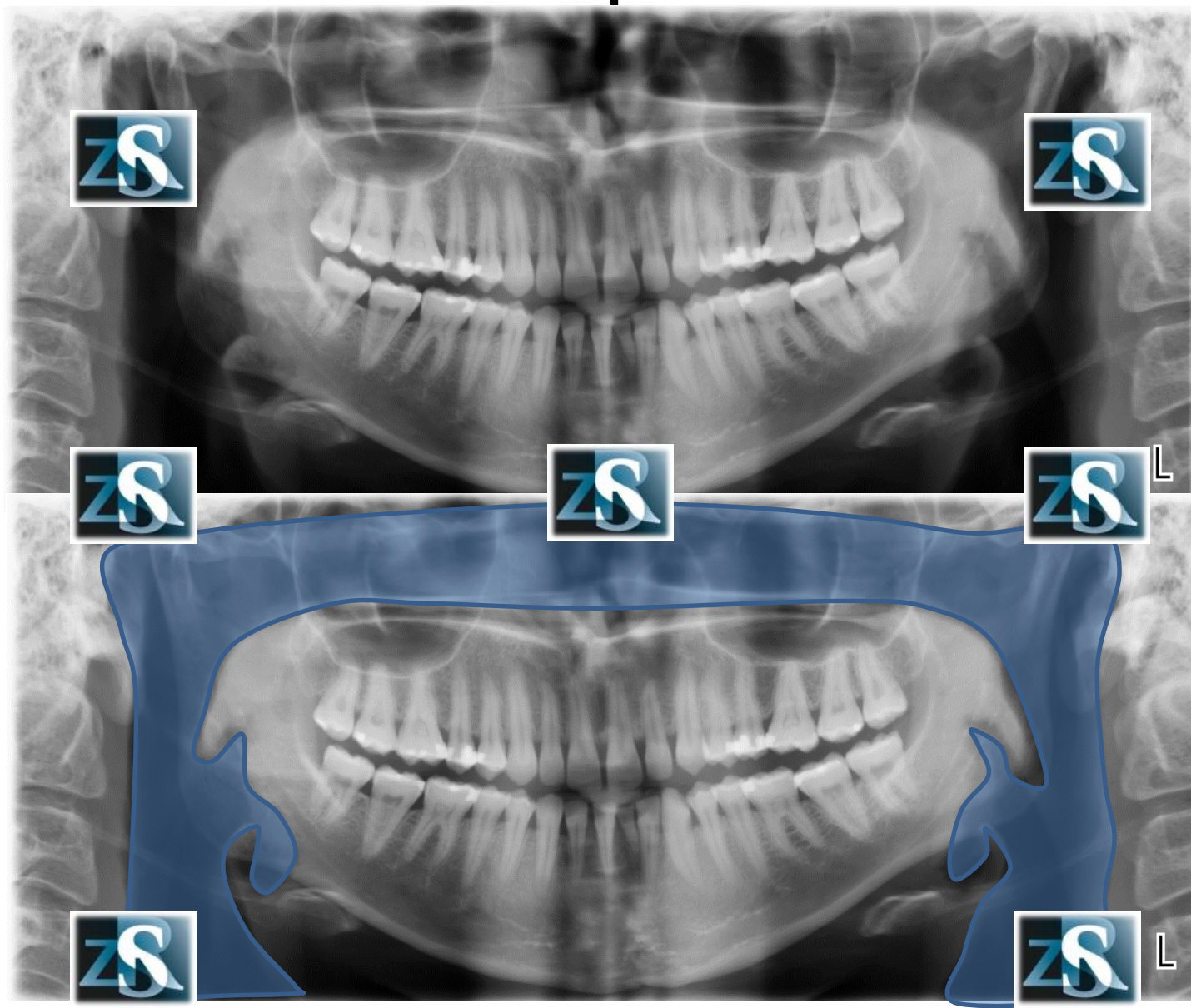
Kolec nosowy przedni



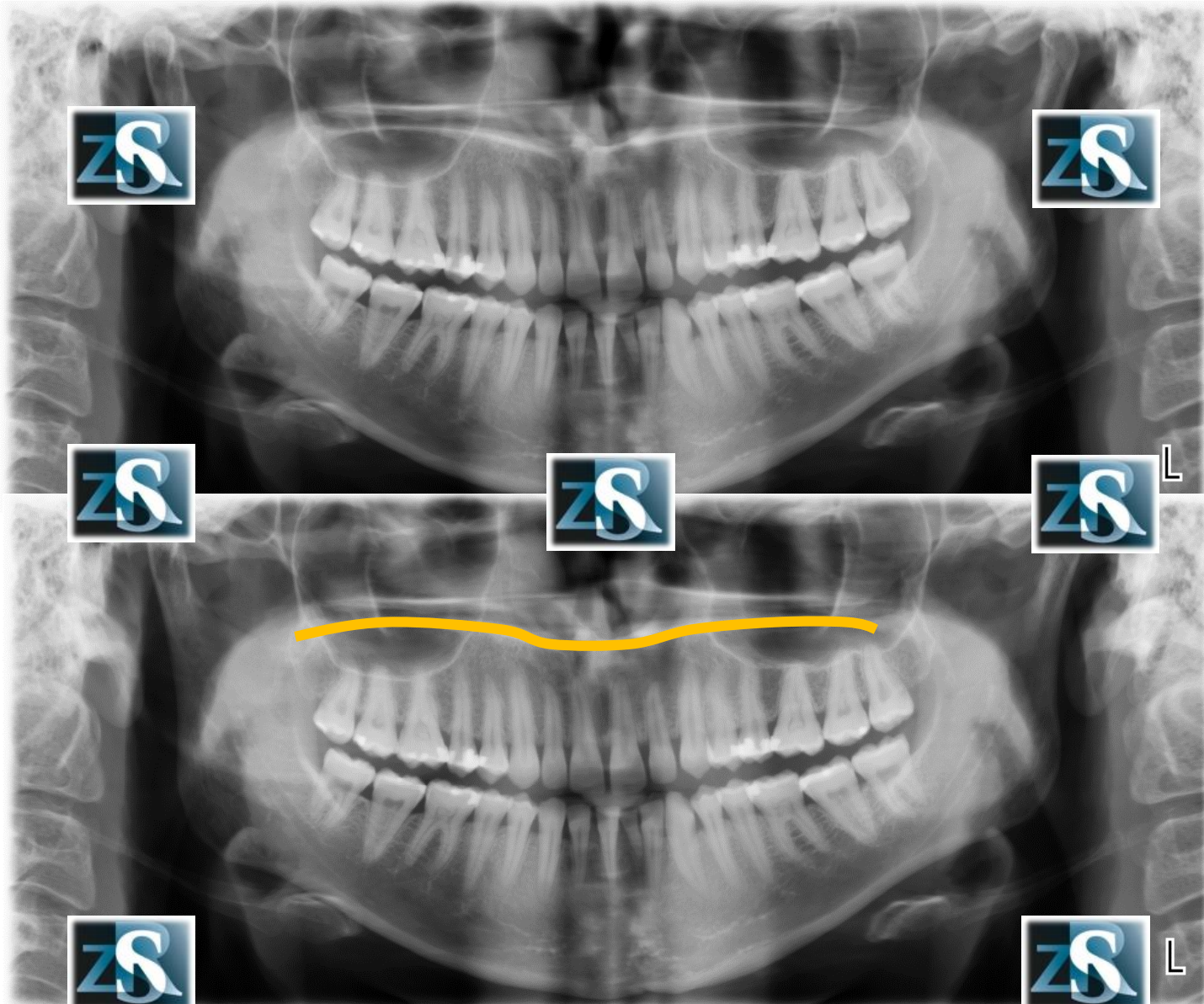
Mażowina nosowa dolna



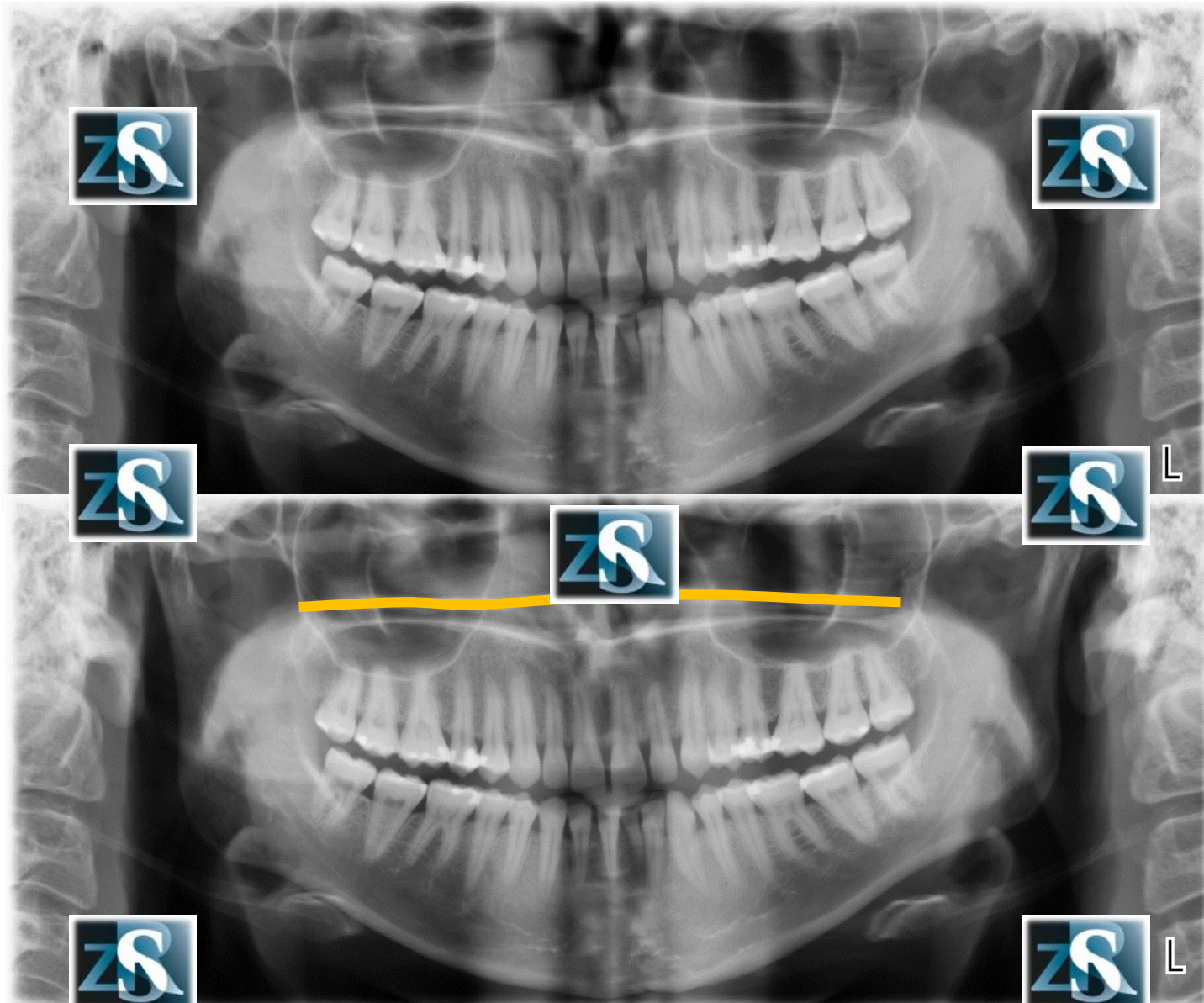
Przestrzeń powietrzna



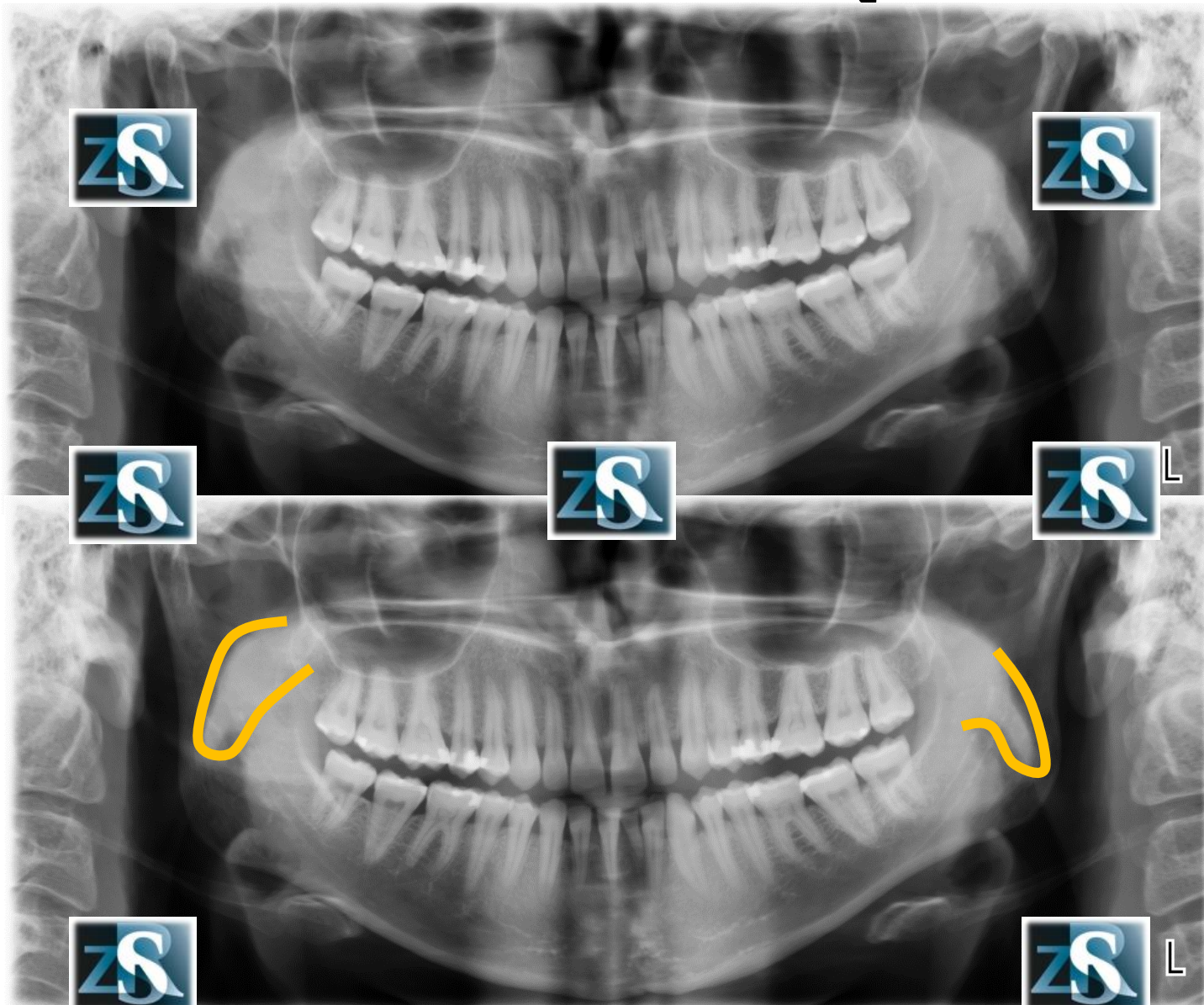
Podniebienie twarde-cień prawdziwy



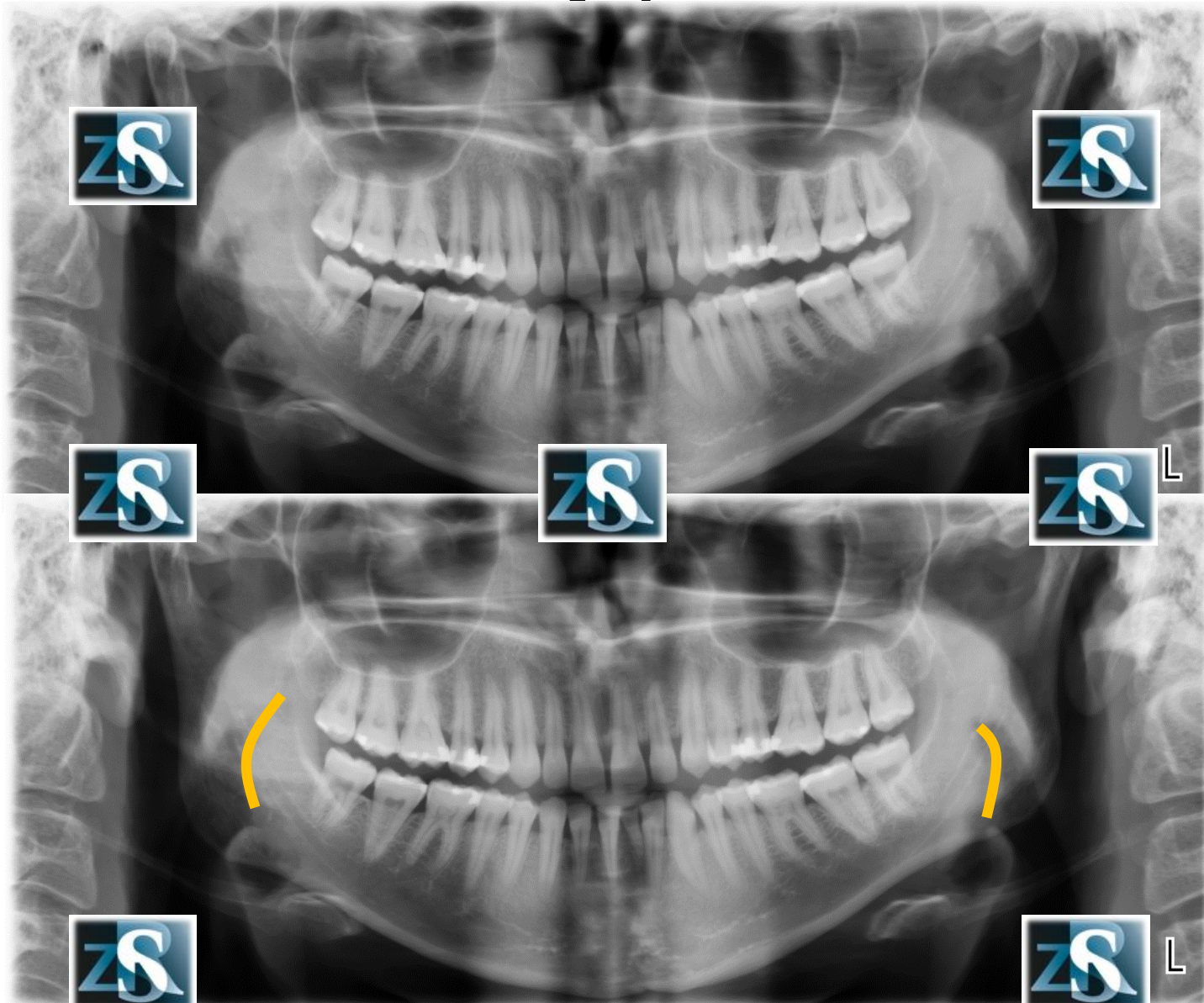
Podniebienie twarde –cień rzekomy



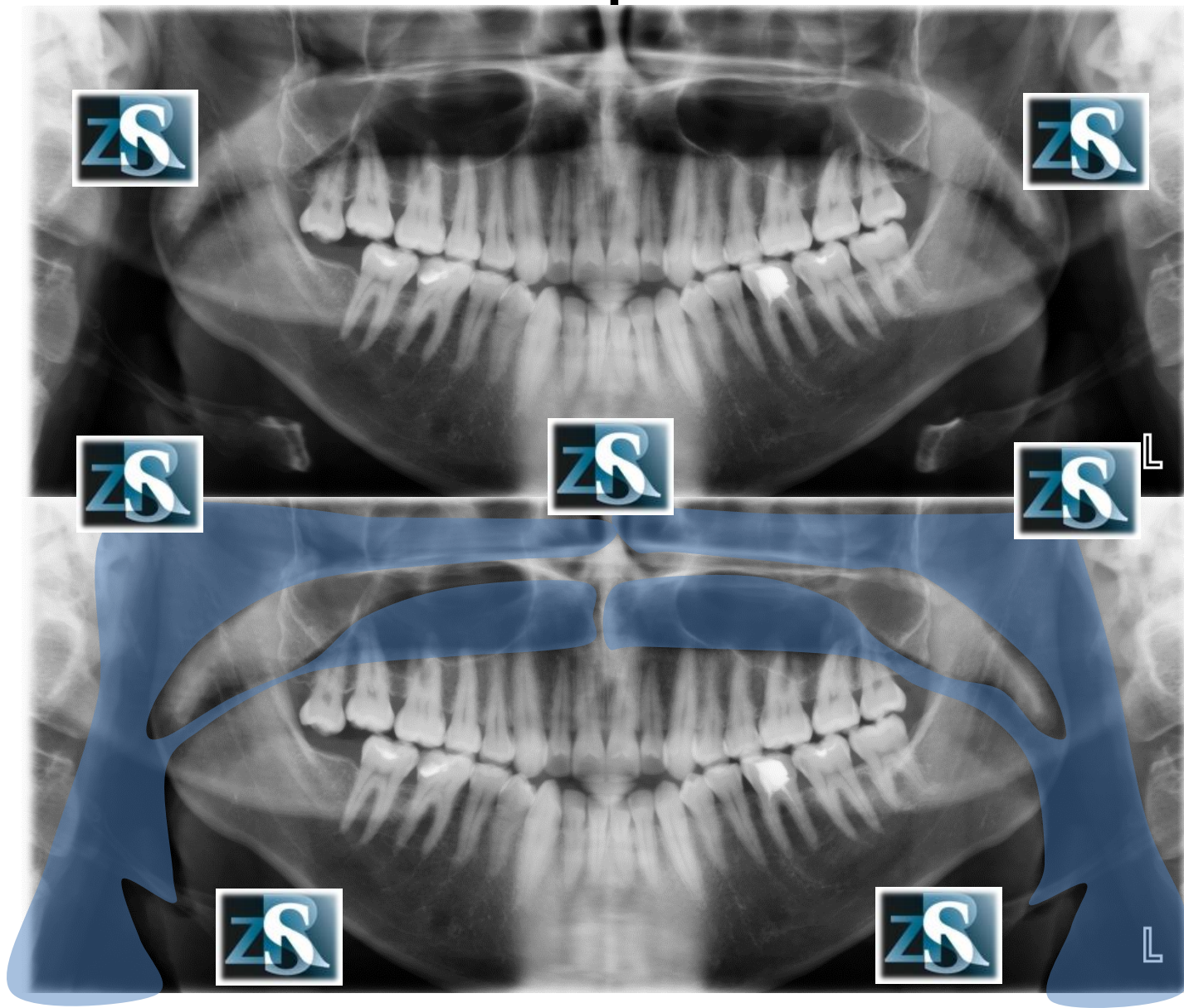
Podniebienie miękkie



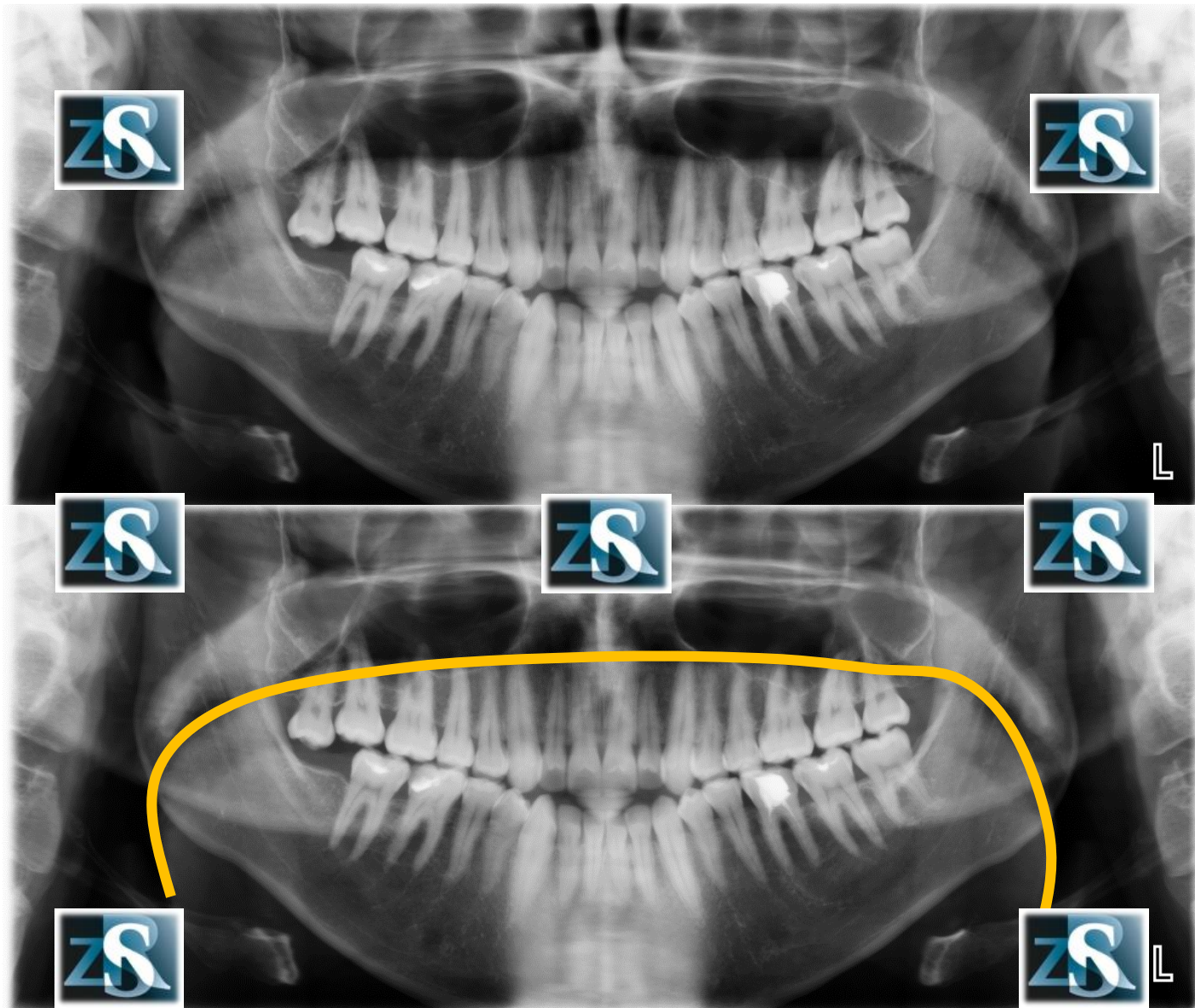
Język



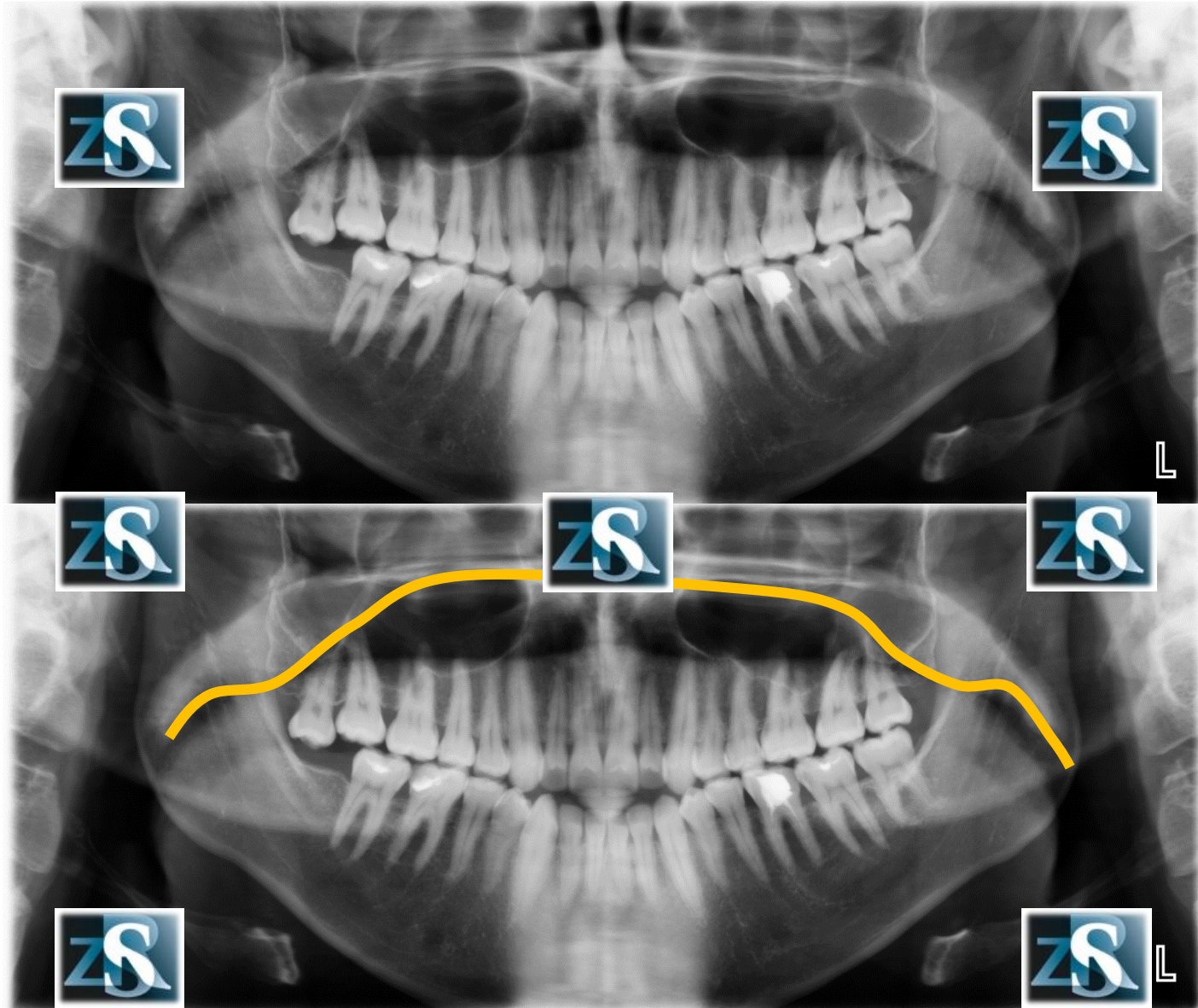
Przestrzeń powietrzna



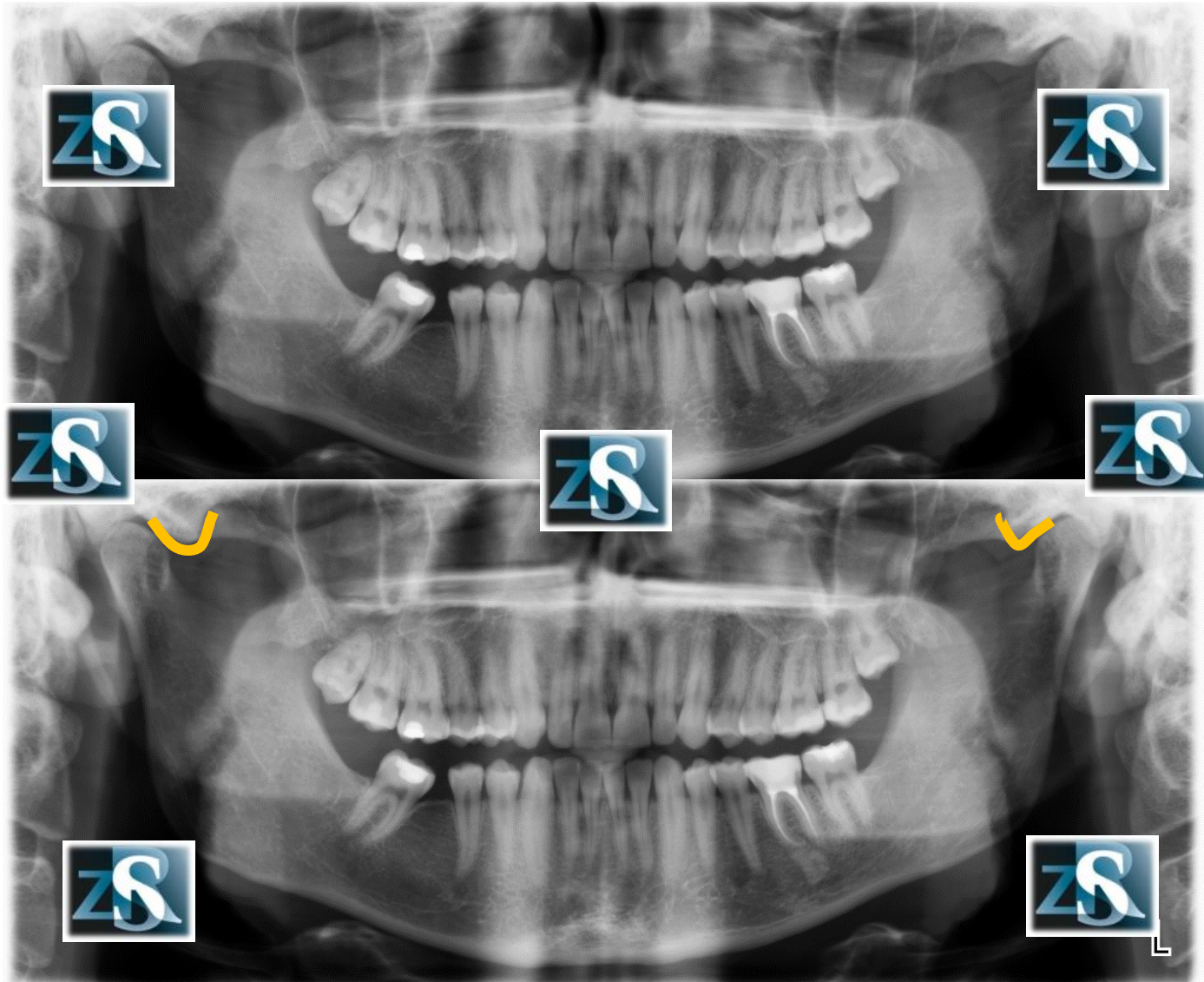
Powierzchnia języka



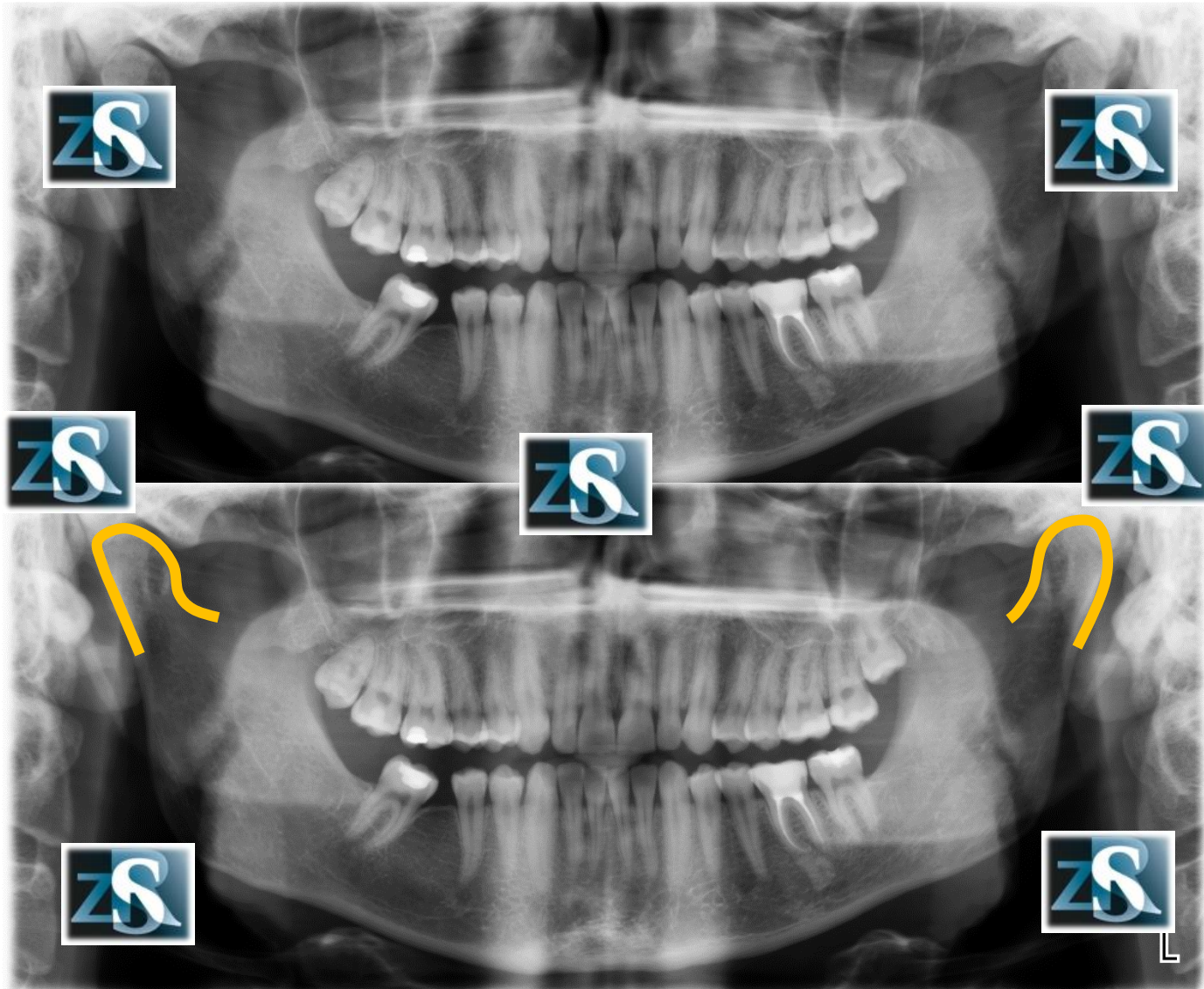
Powierzchnia podniebienia



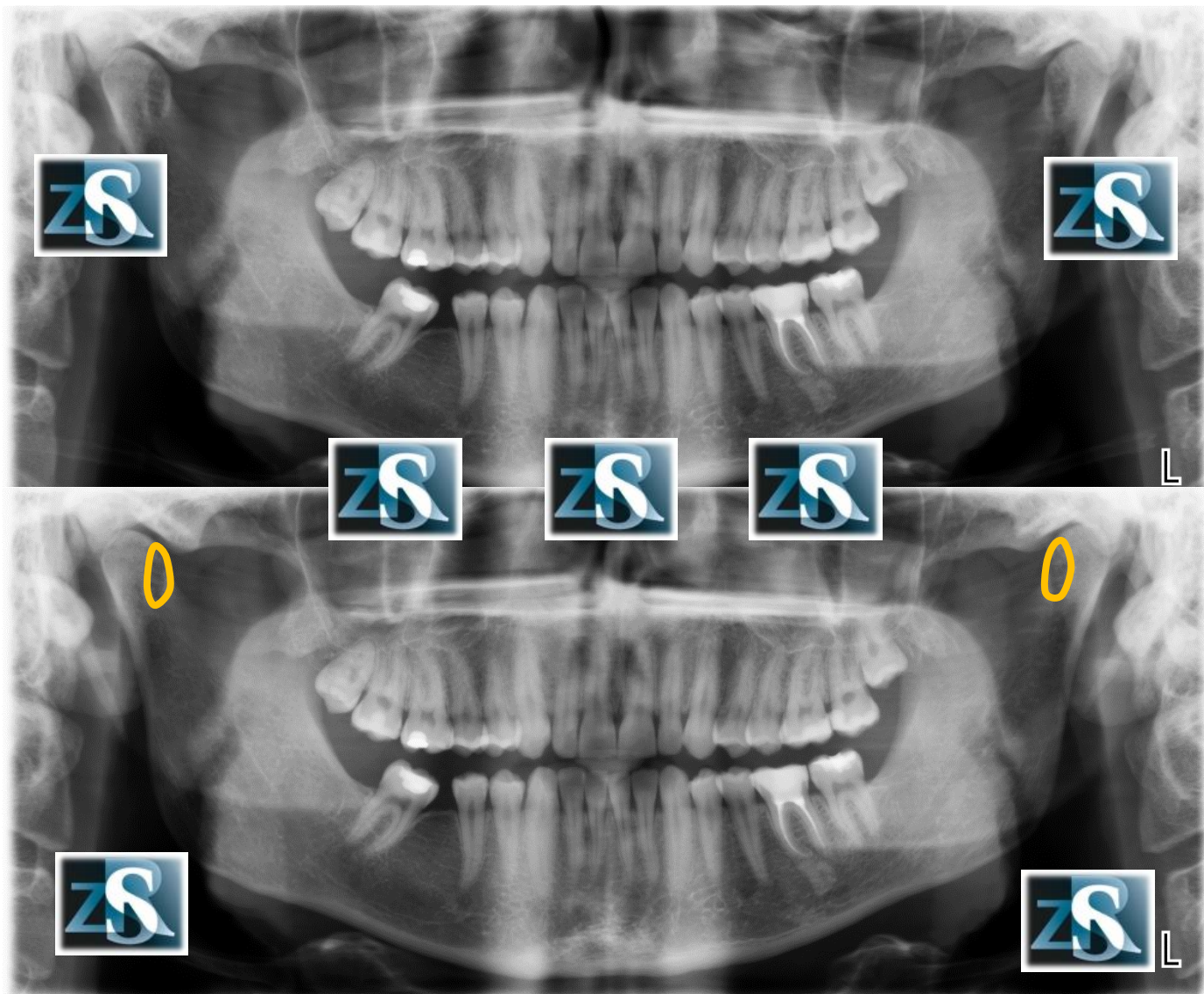
Guzek stawowy



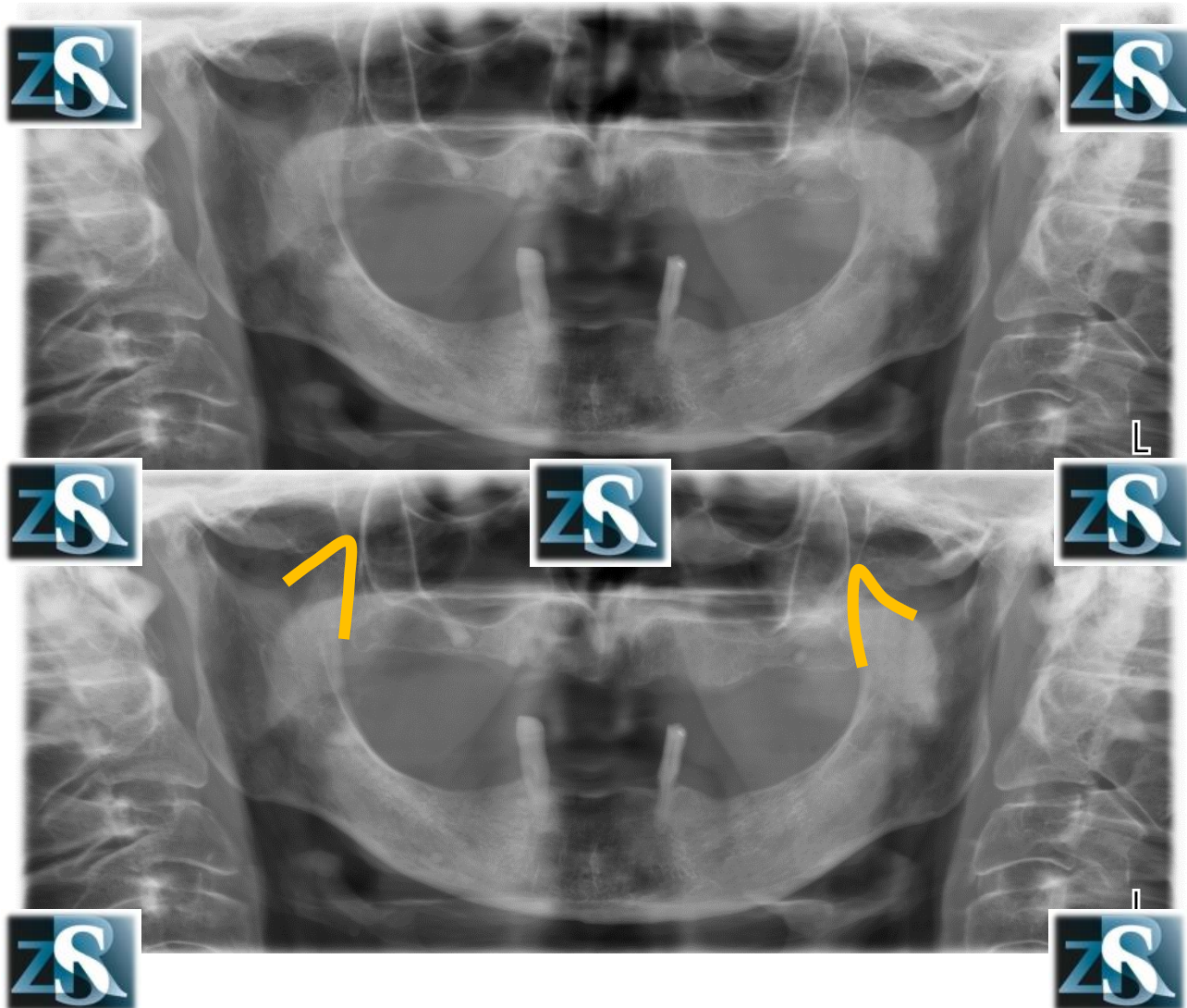
Wyrastki kłykciovve



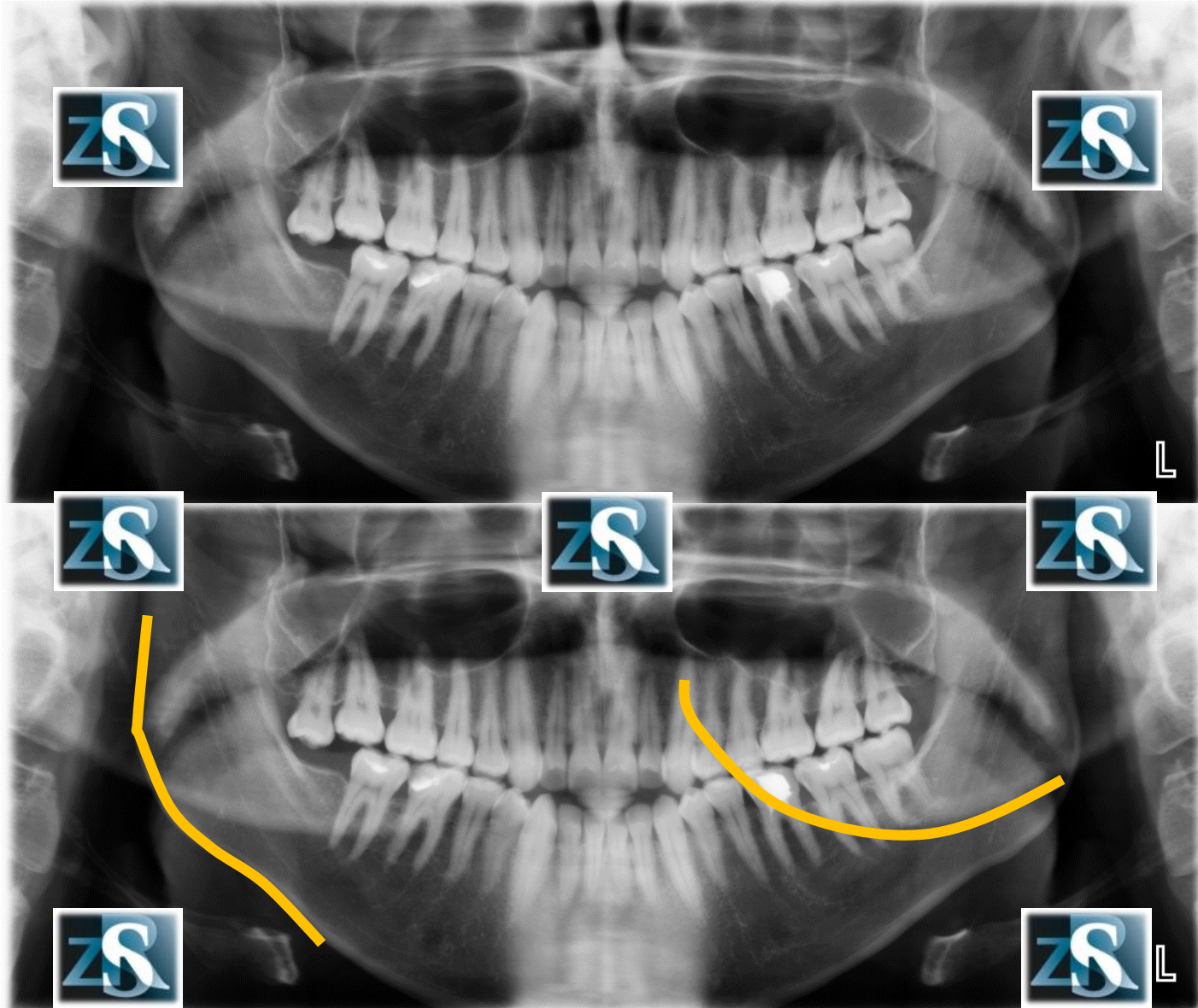
Dołki skrzydłowe



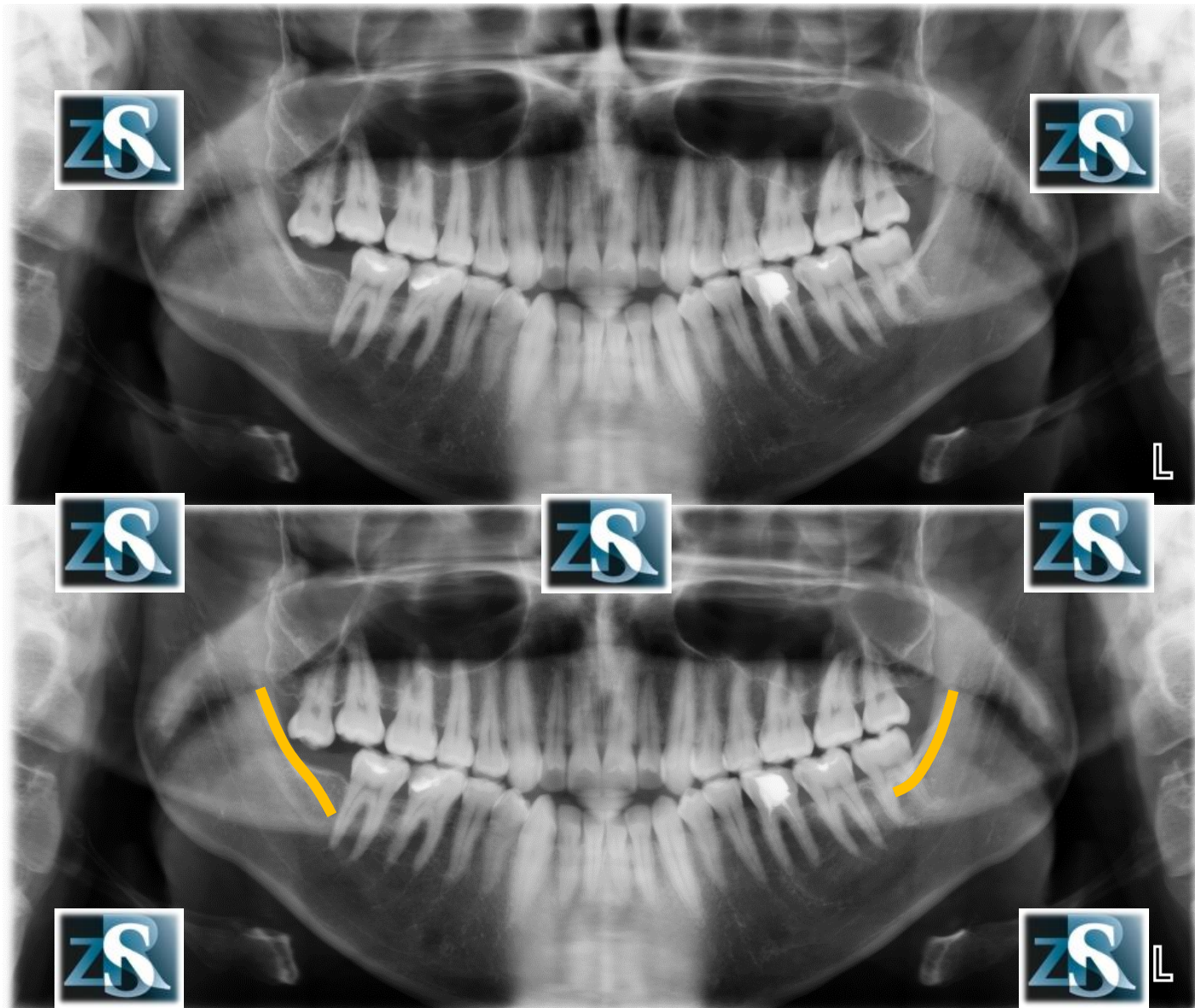
Wyrostki dziobiaste



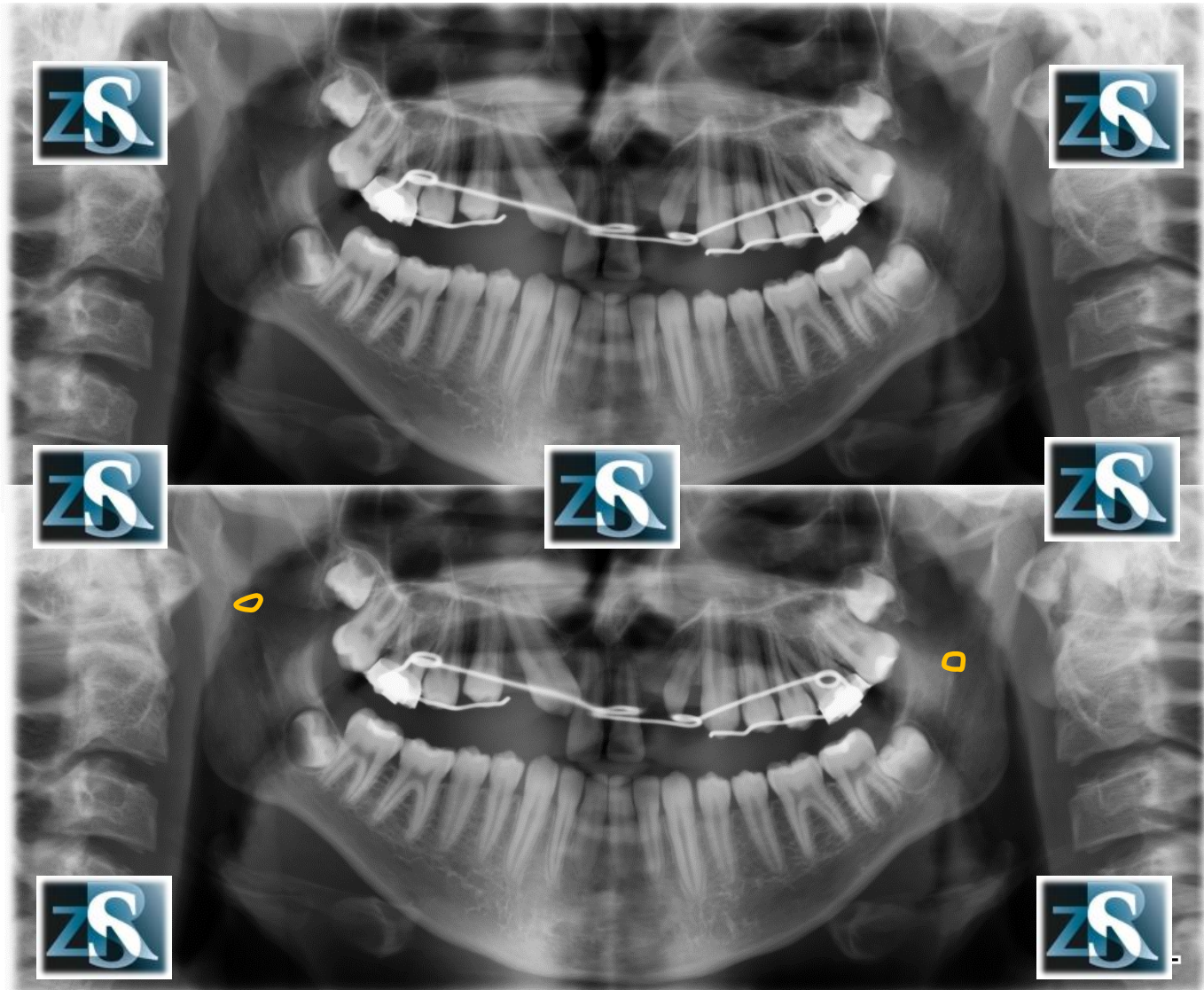
Prawy kąt żuchwy (cień prawdziwy i rzekomy)



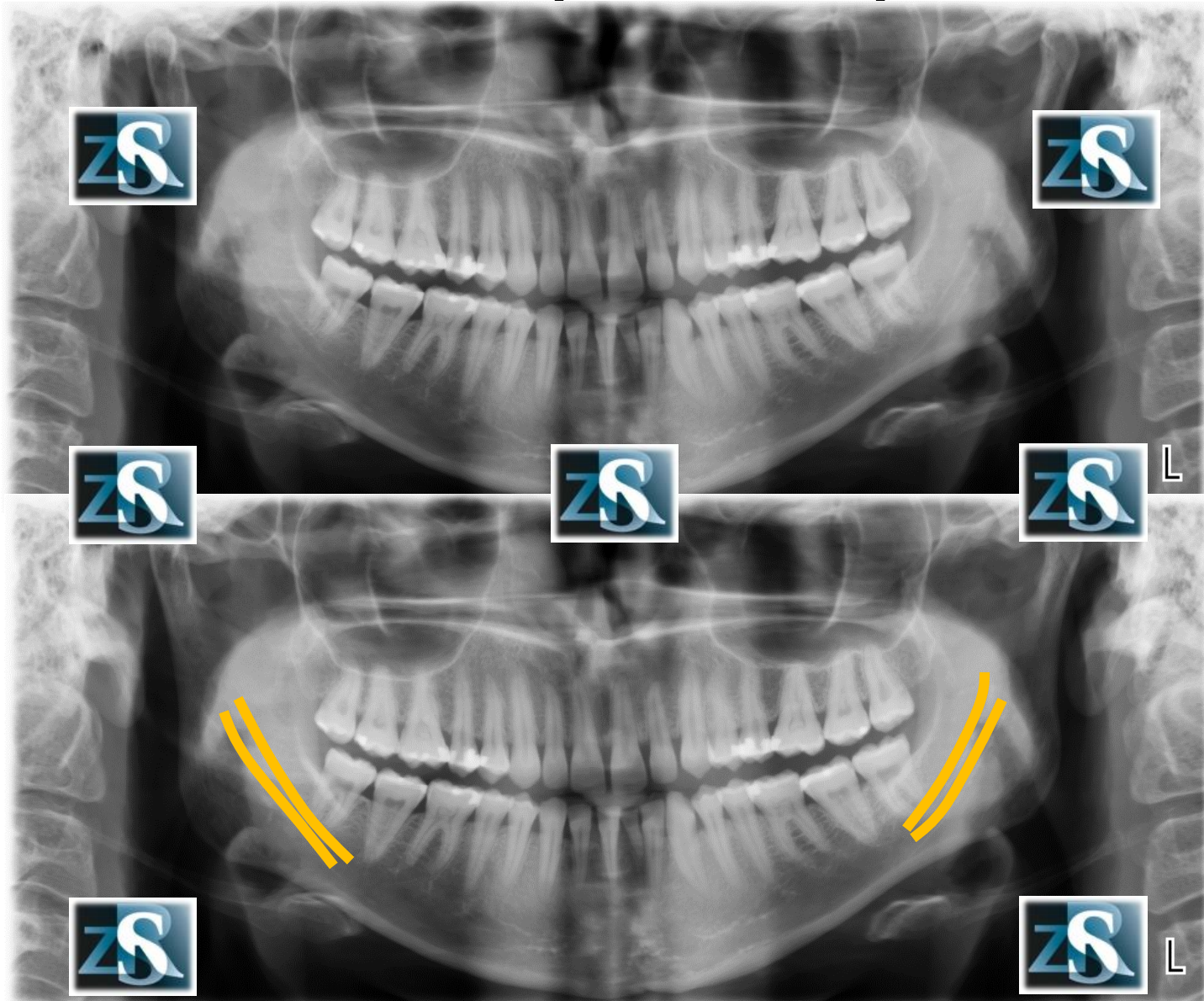
Kresa skośna



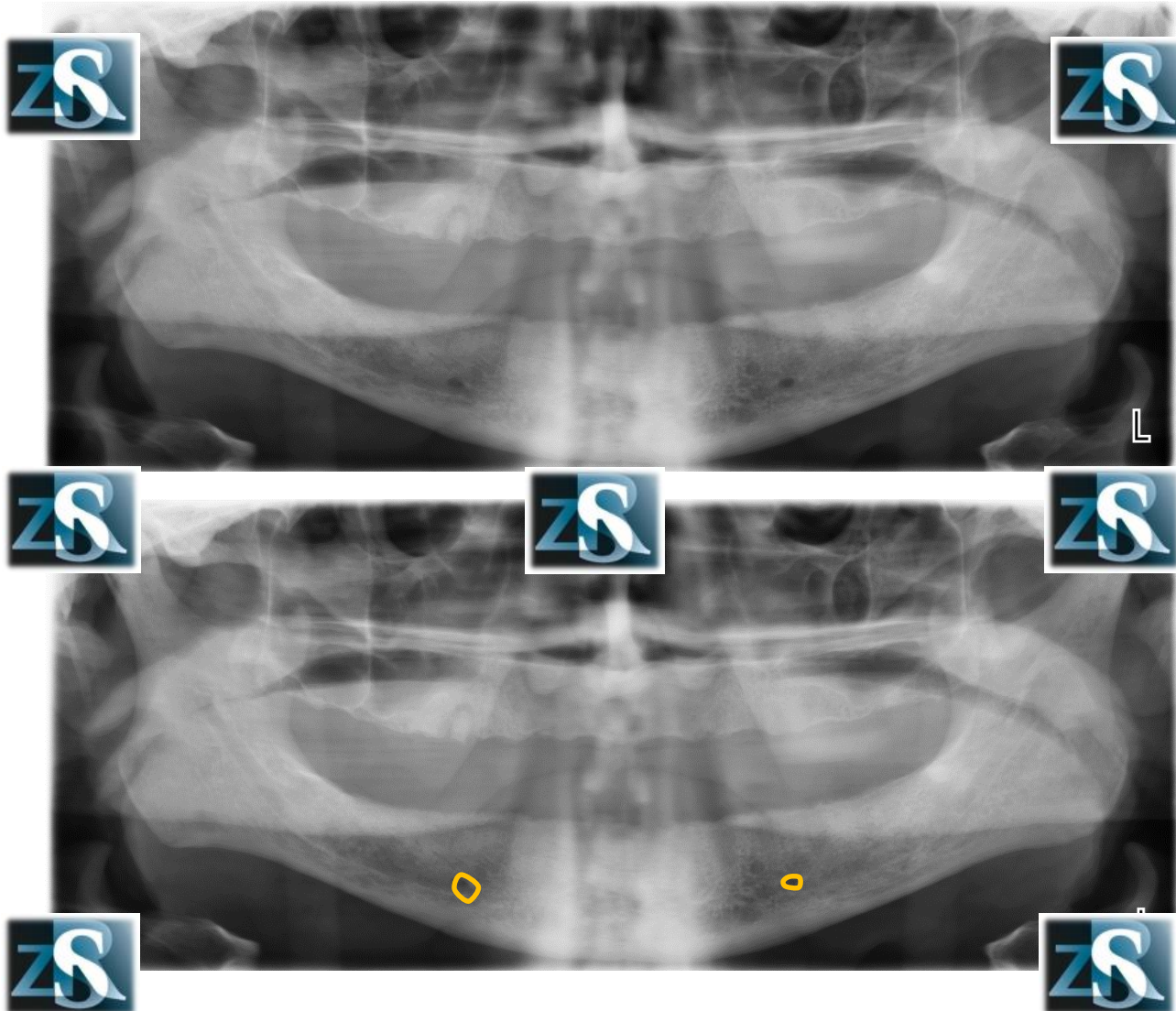
Otwory zuchwowe



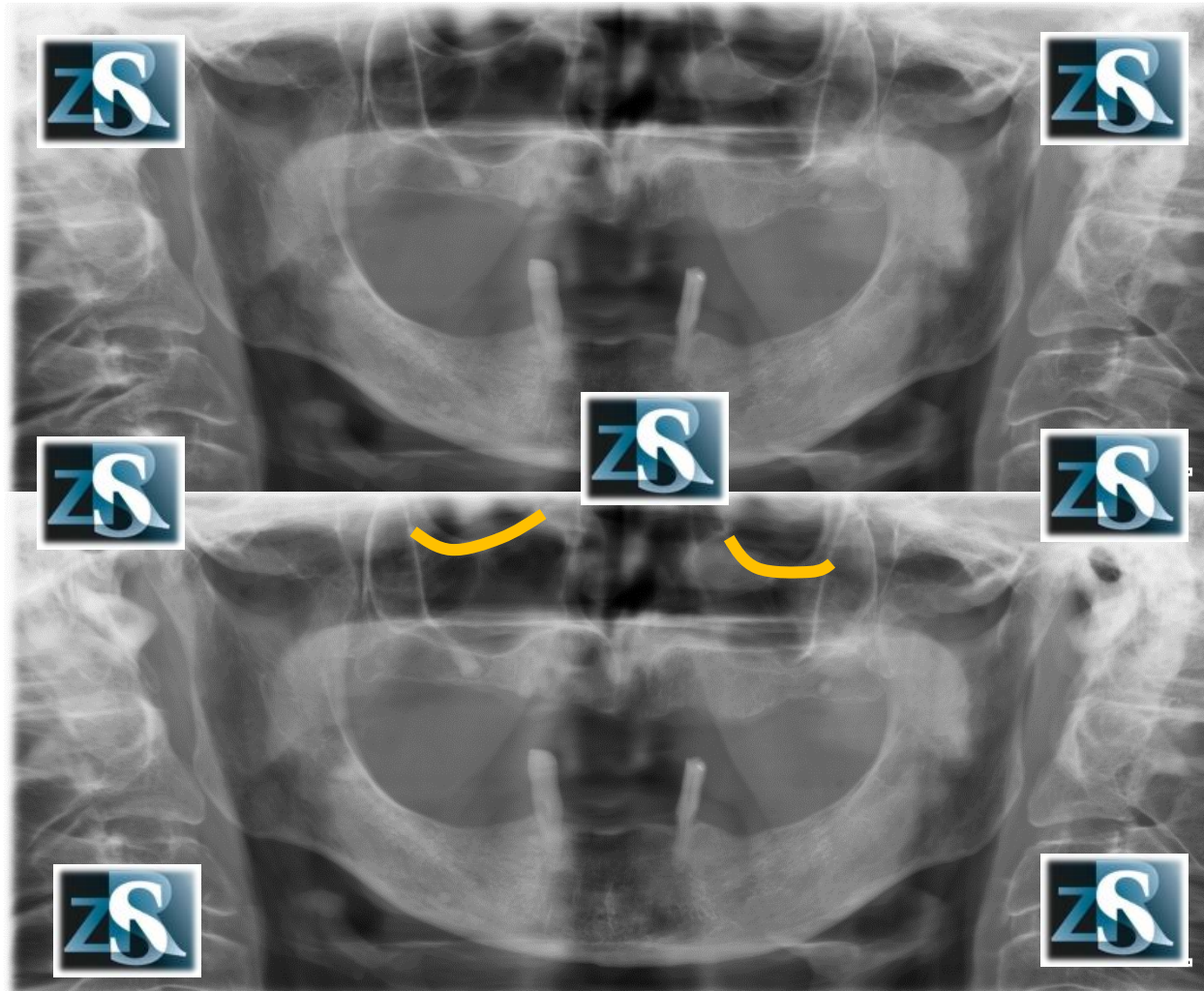
Kanały zuchwy



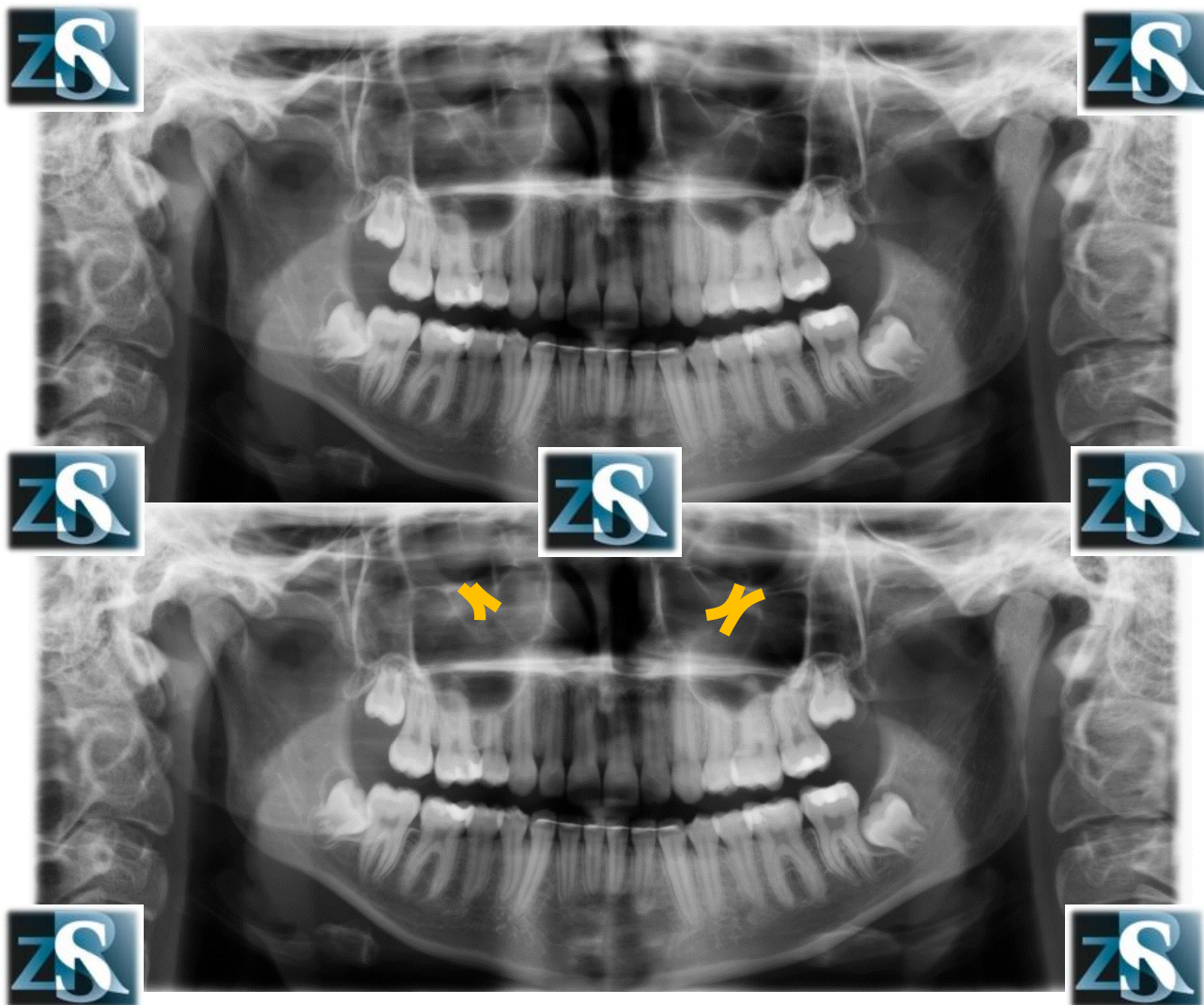
Otwory bródkowe



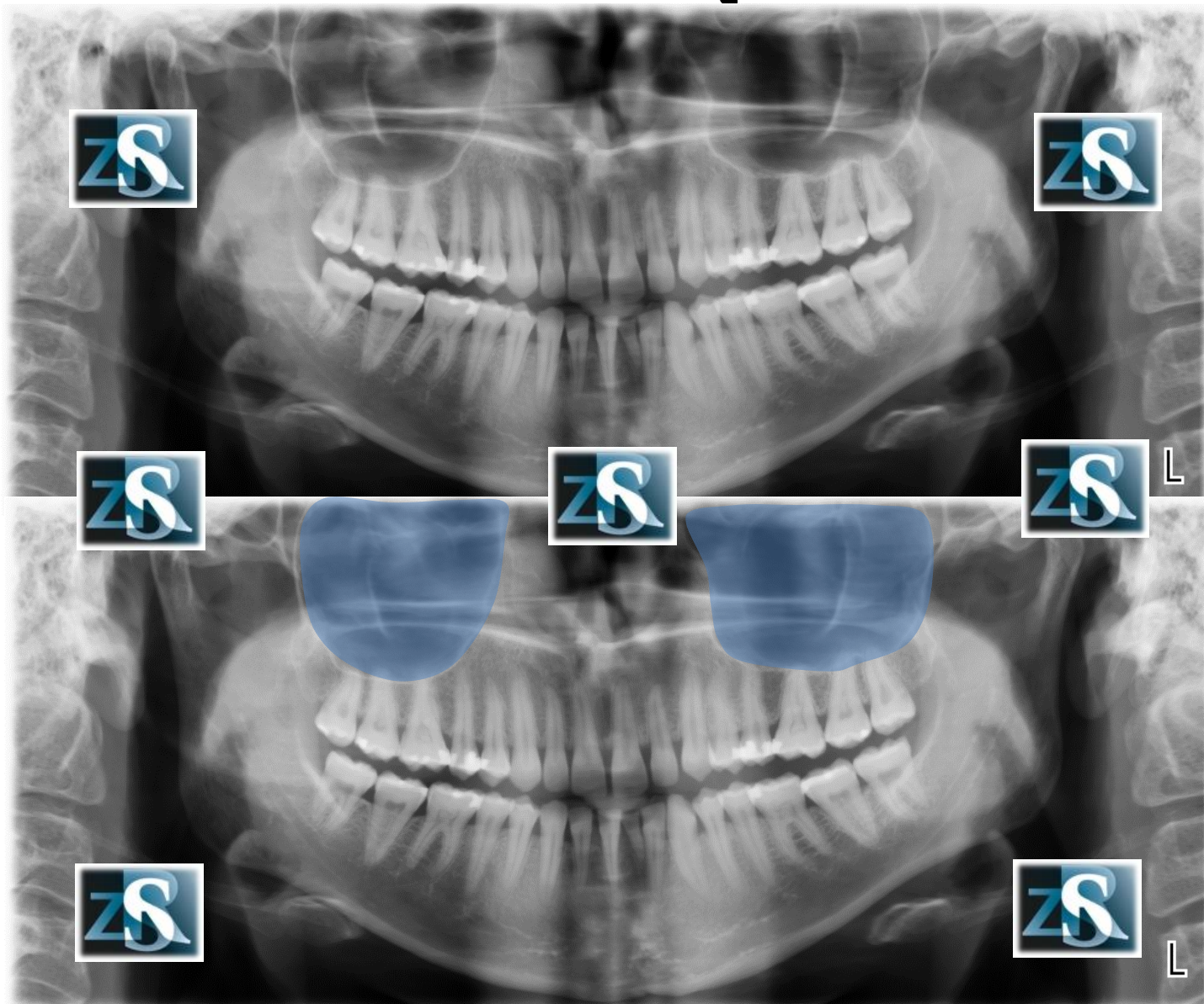
Dno oczodołów



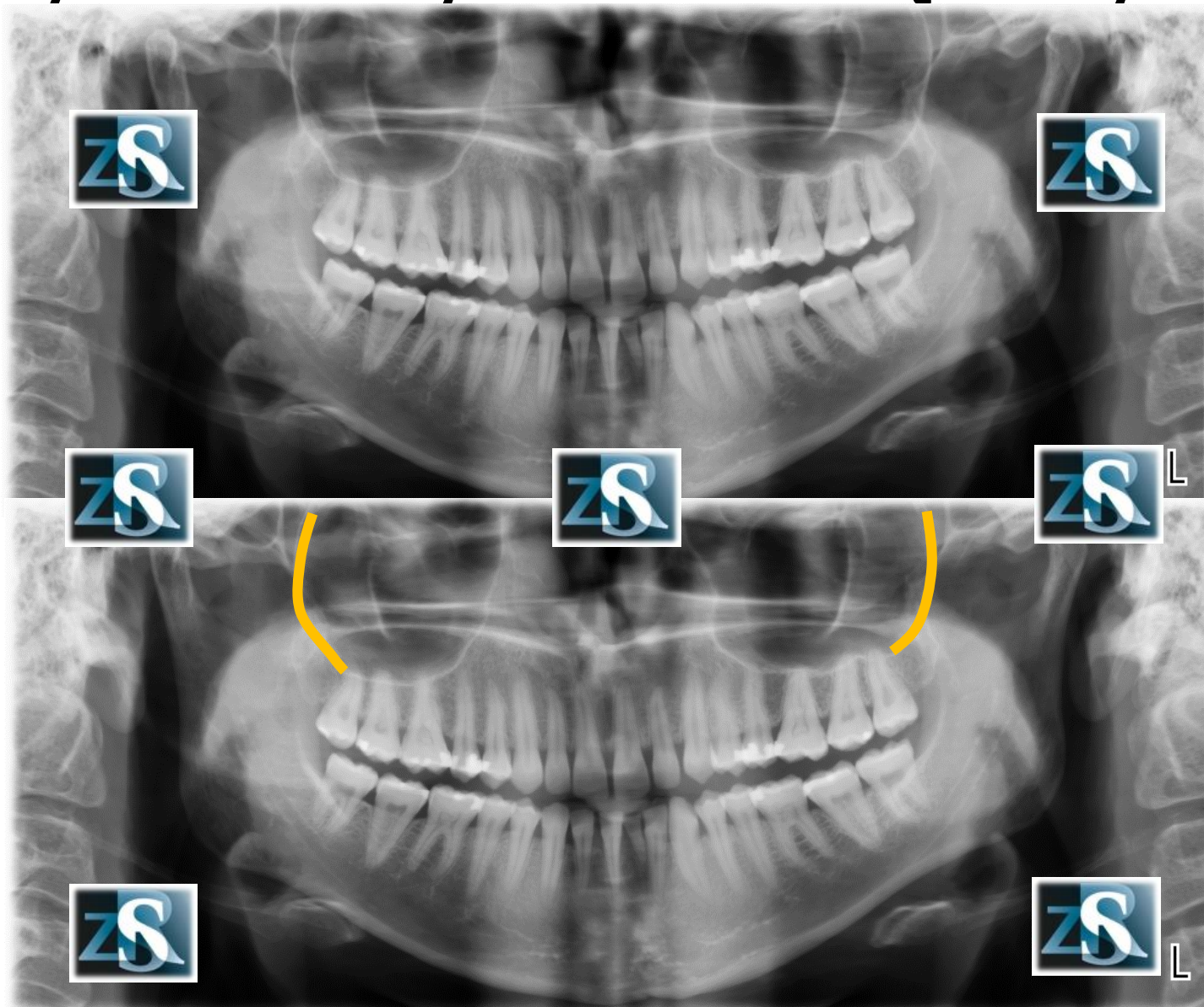
Kanały podoczodołowe



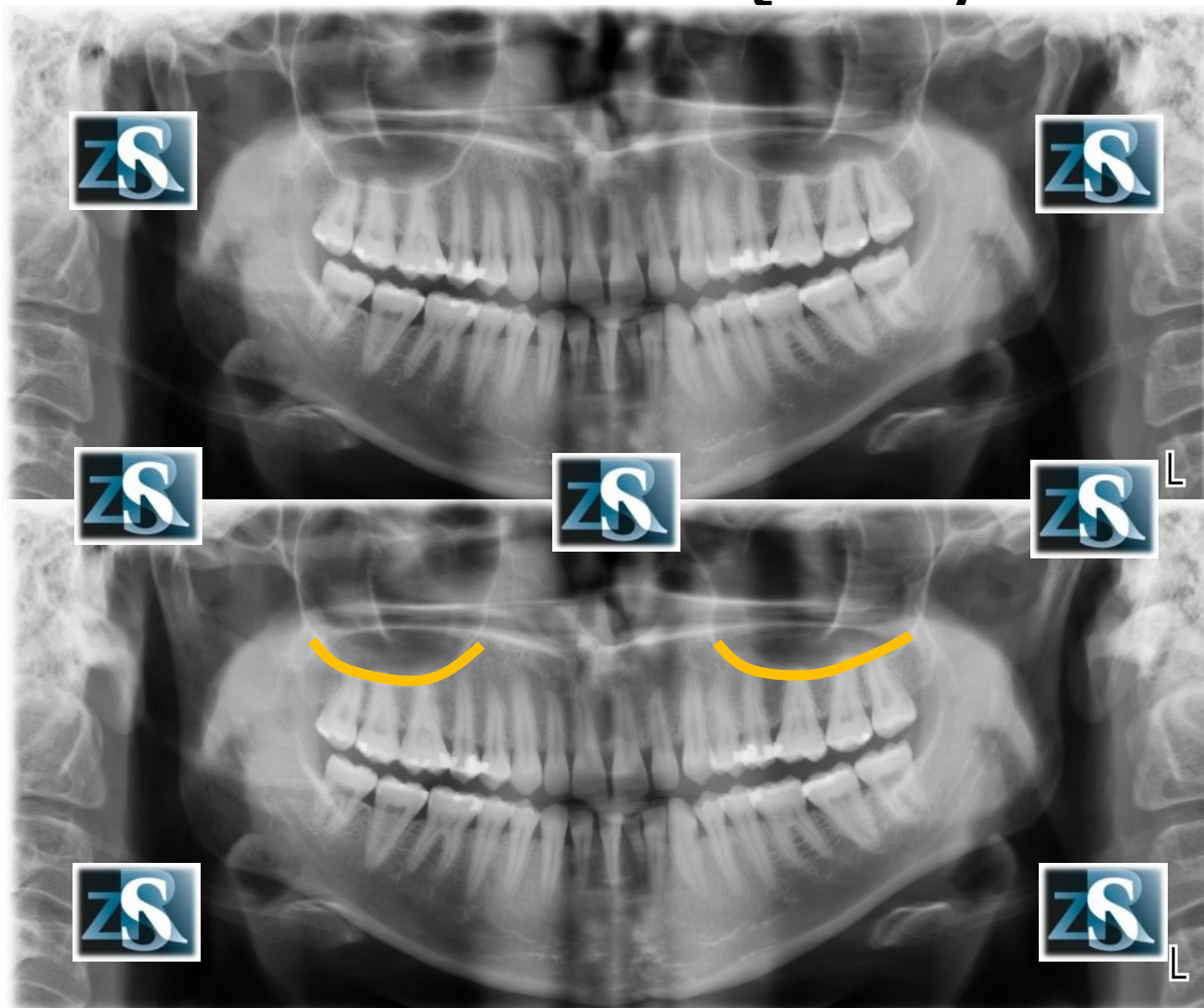
Zatoki szczękowe



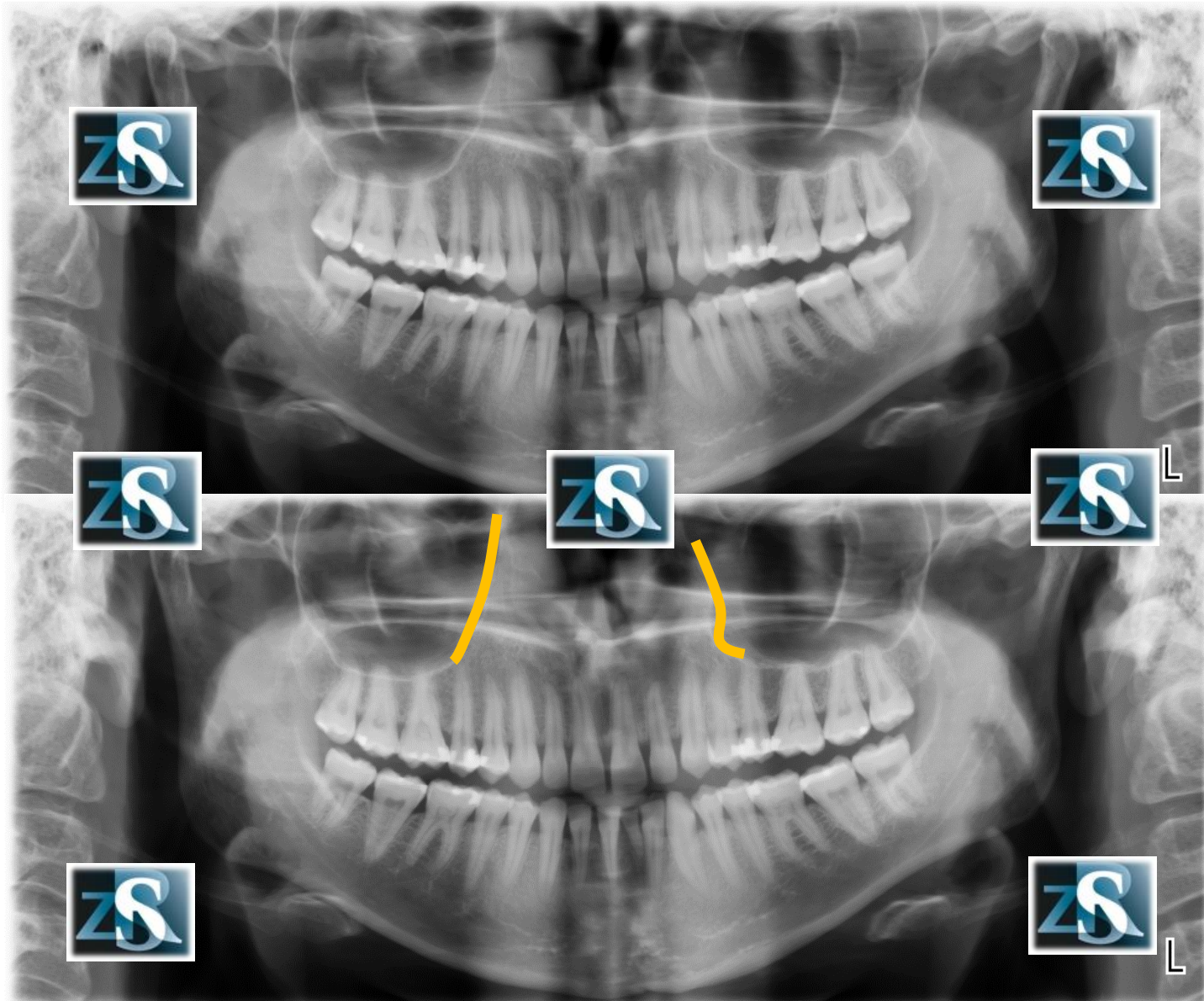
Tylne ściany zatok szczękowych



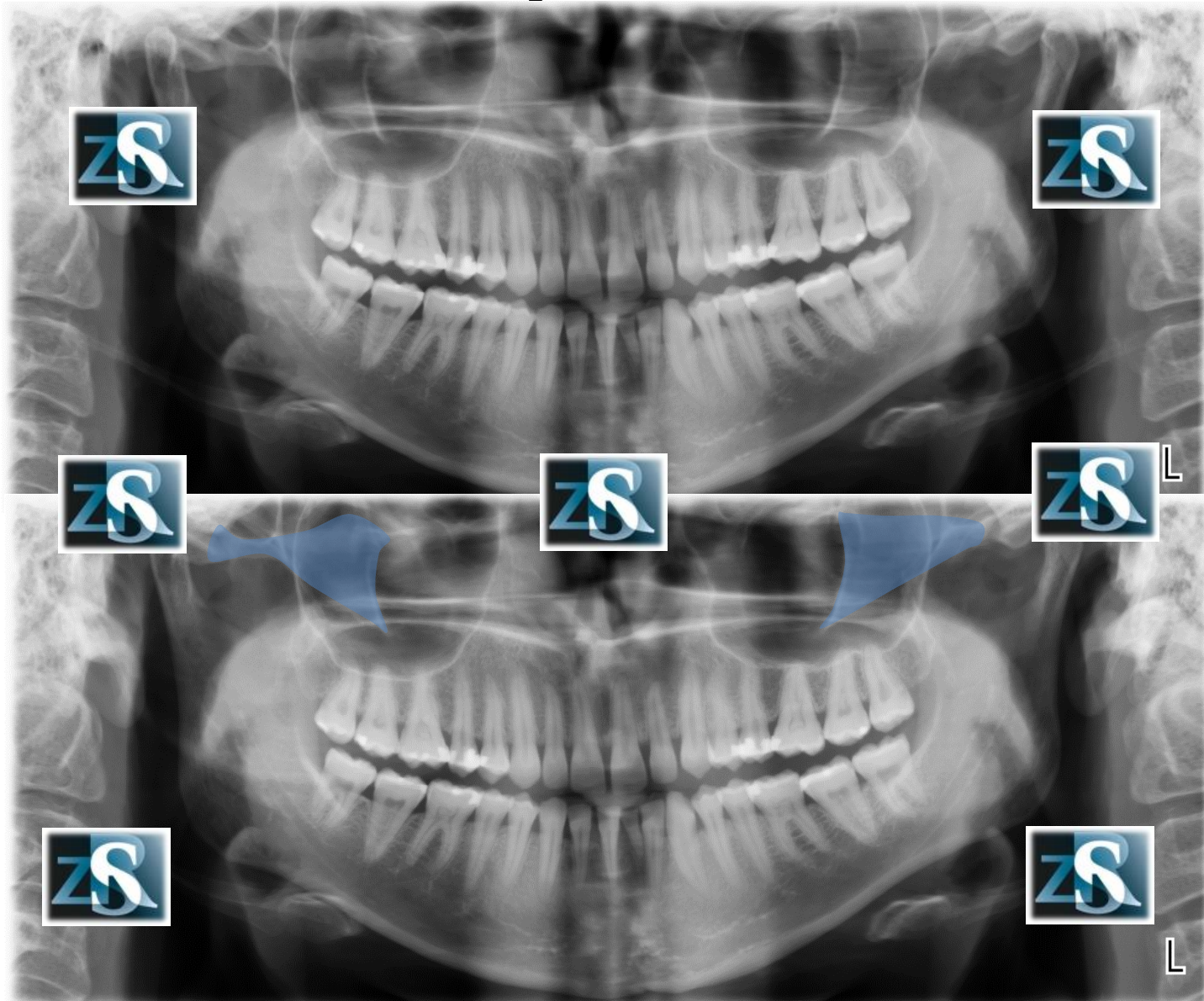
Dno zatok szczękowych



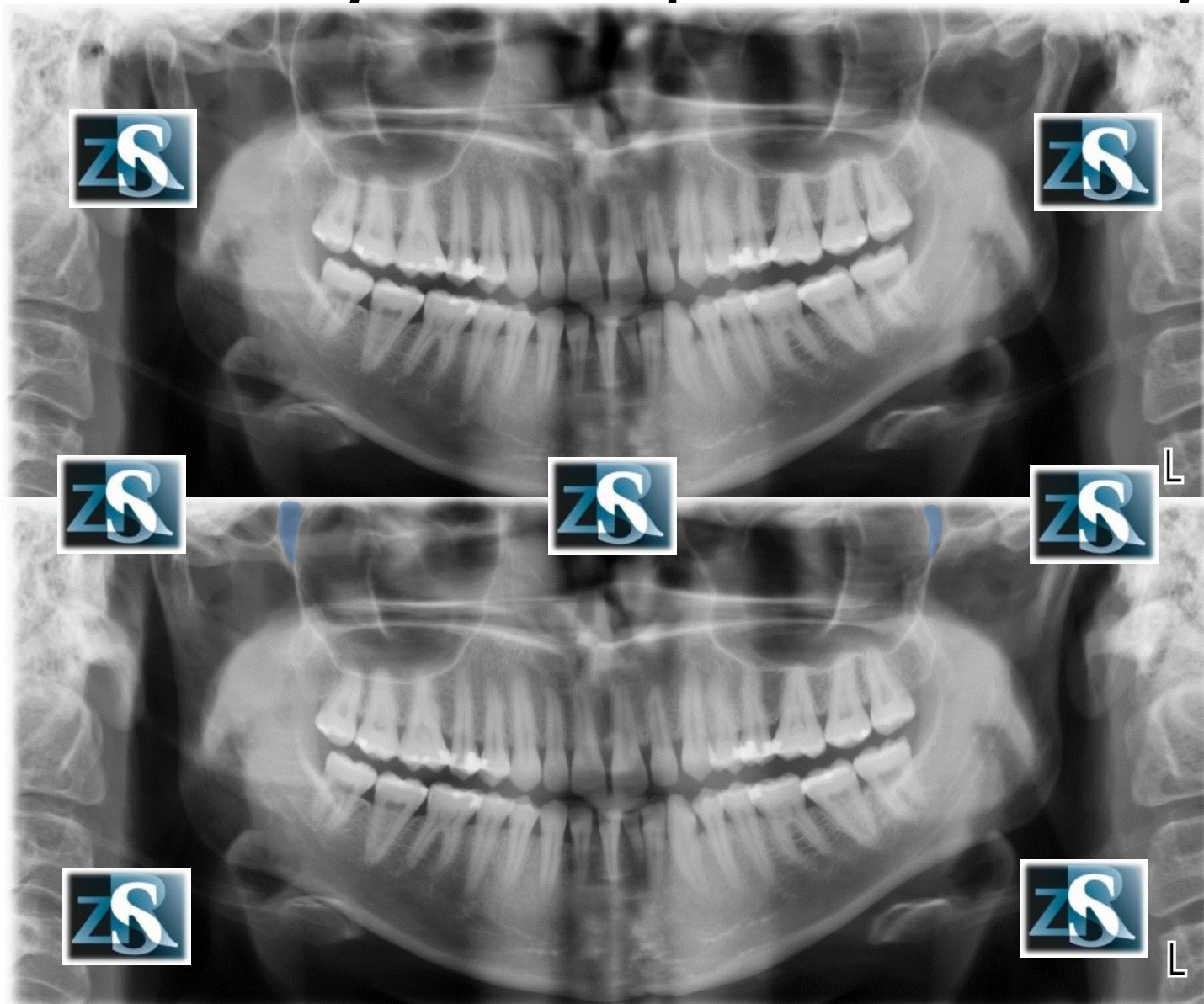
Ściany przyśrodkowe zatok szczękowych



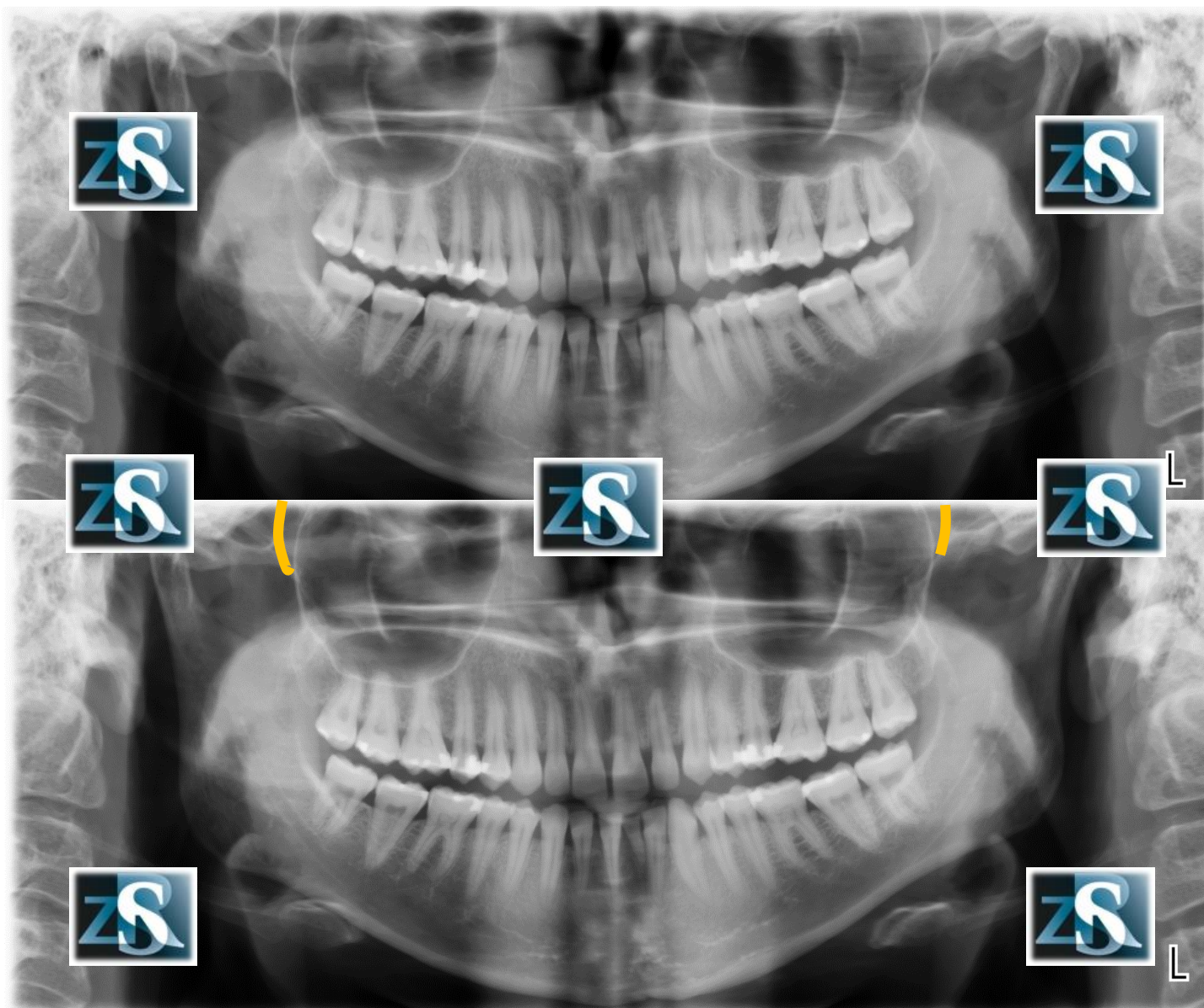
Kości jarzmowe



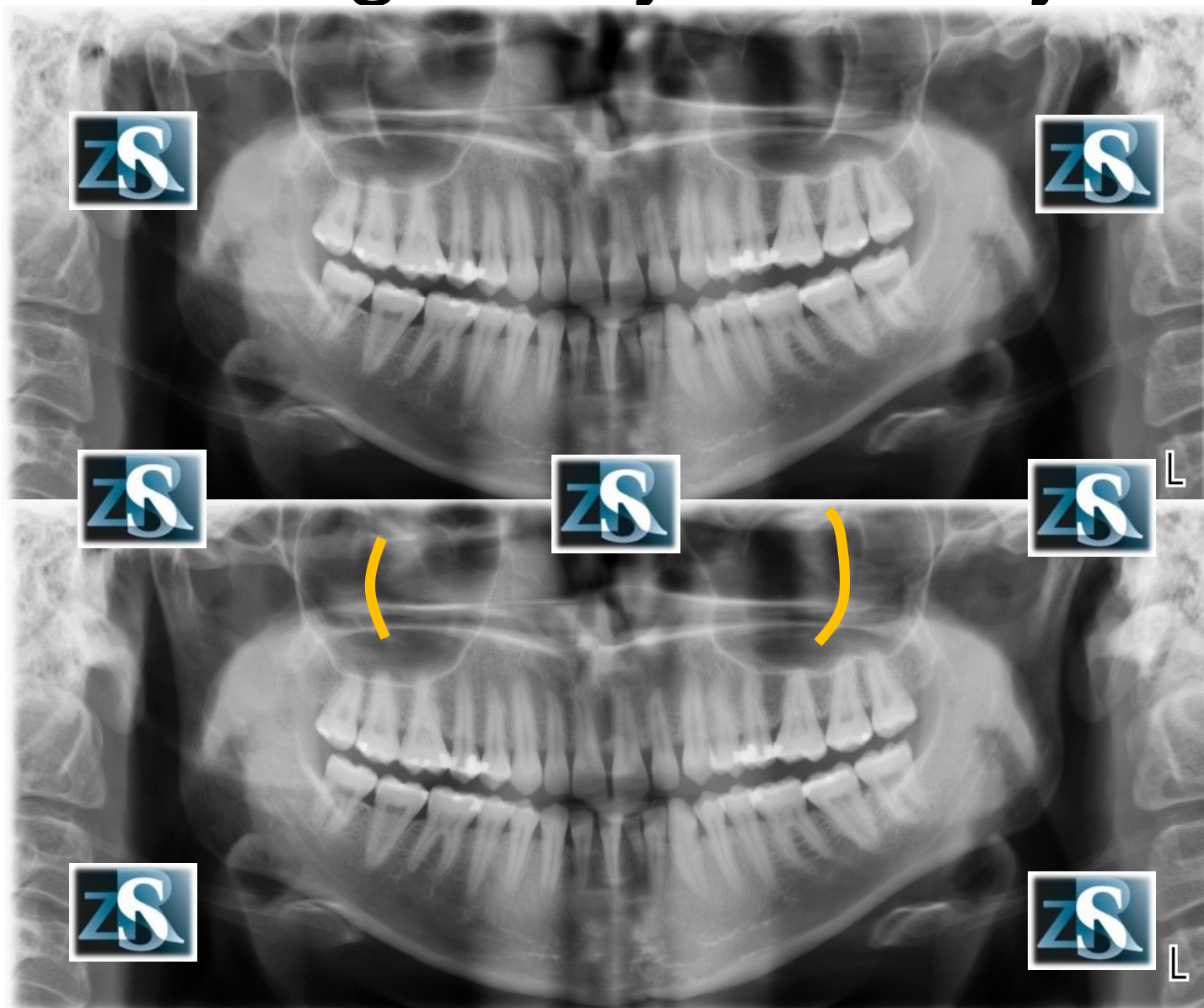
Dół skrzydłowo-podniebienny



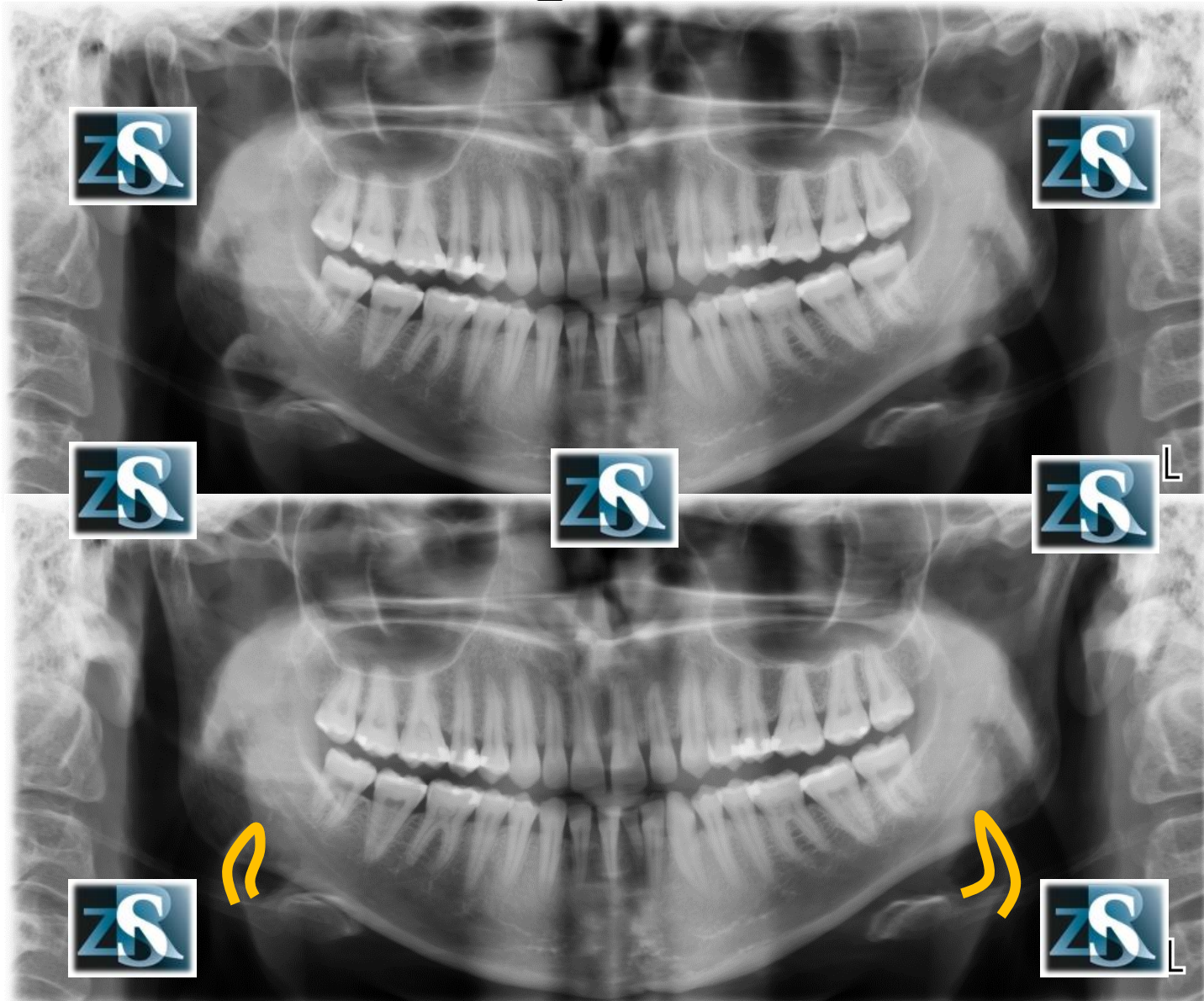
Blaszka boczna wyrostka skrzydłowego kości klinowej



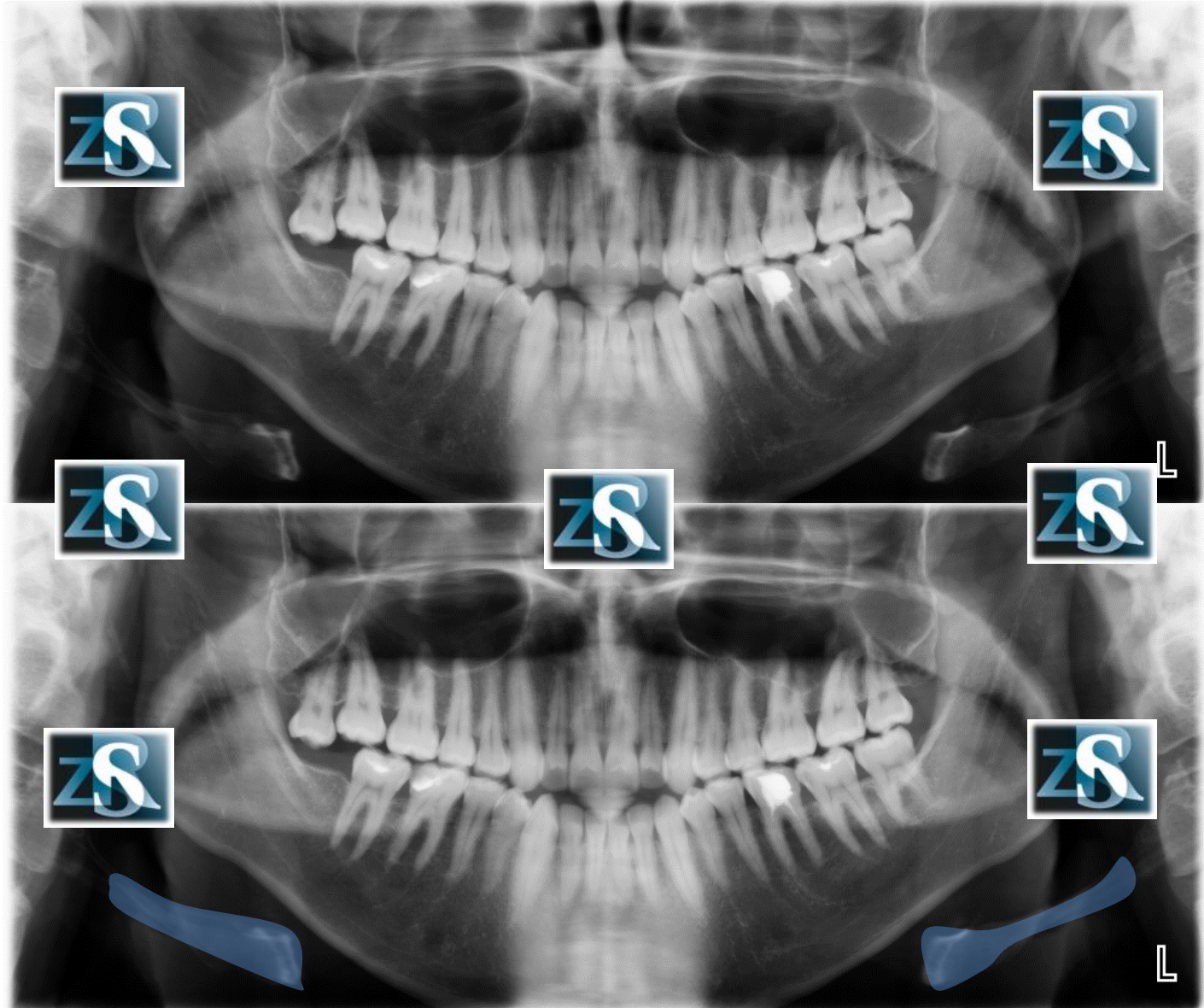
Brzeg kości jarzmowej



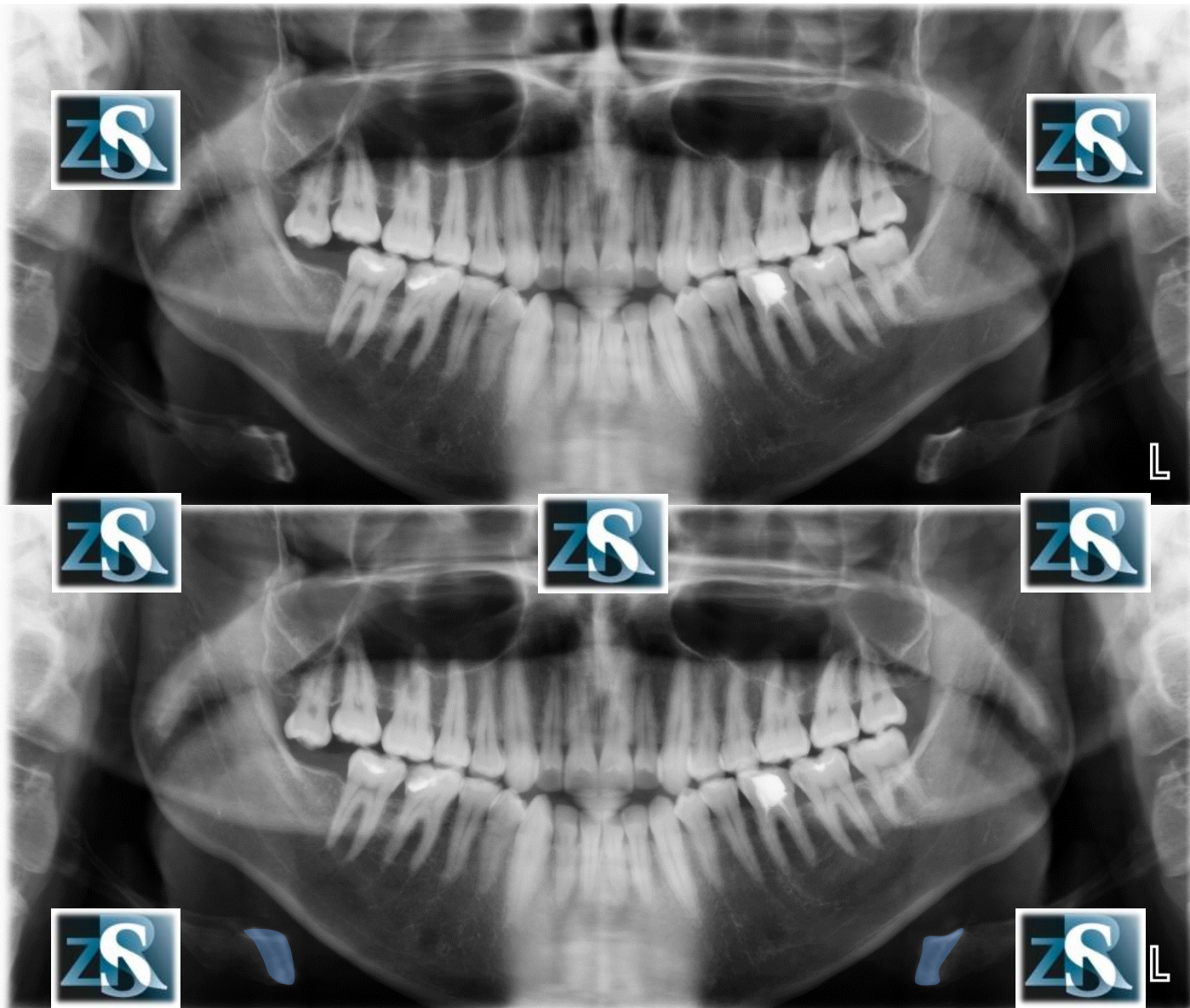
Nagłośnia



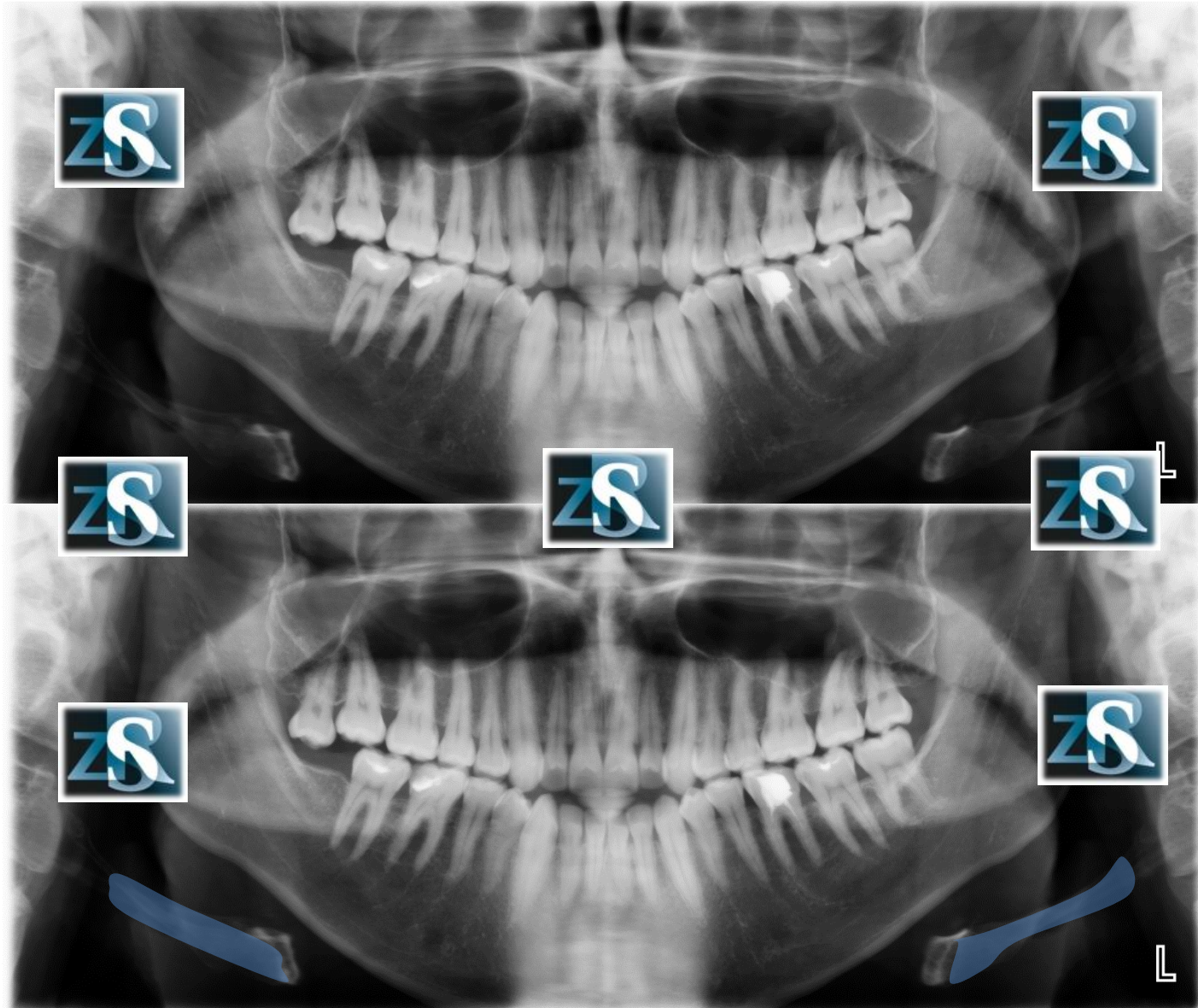
Kość gnykowa



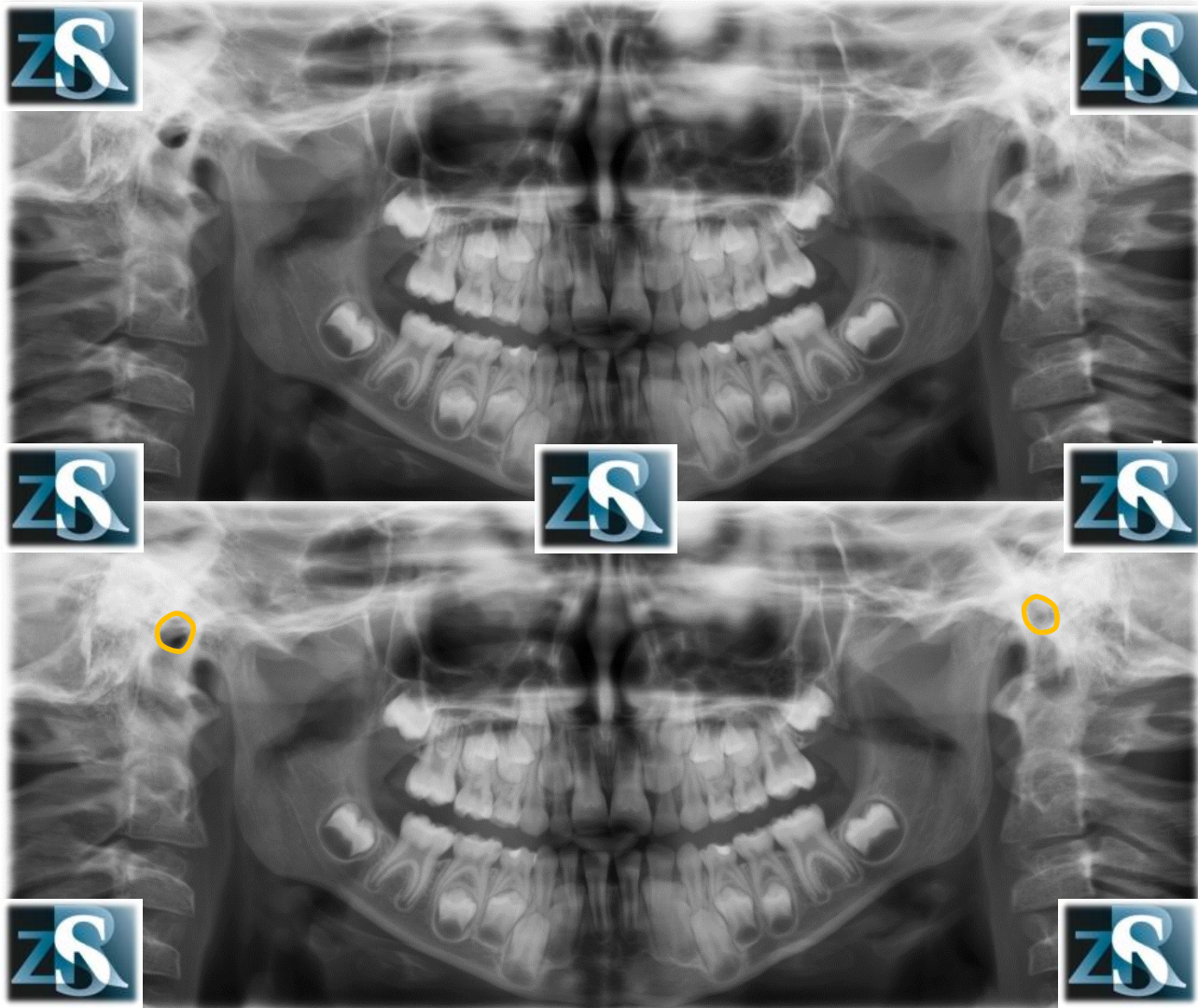
Kość gnykowa-trzon, rogi mniejsze



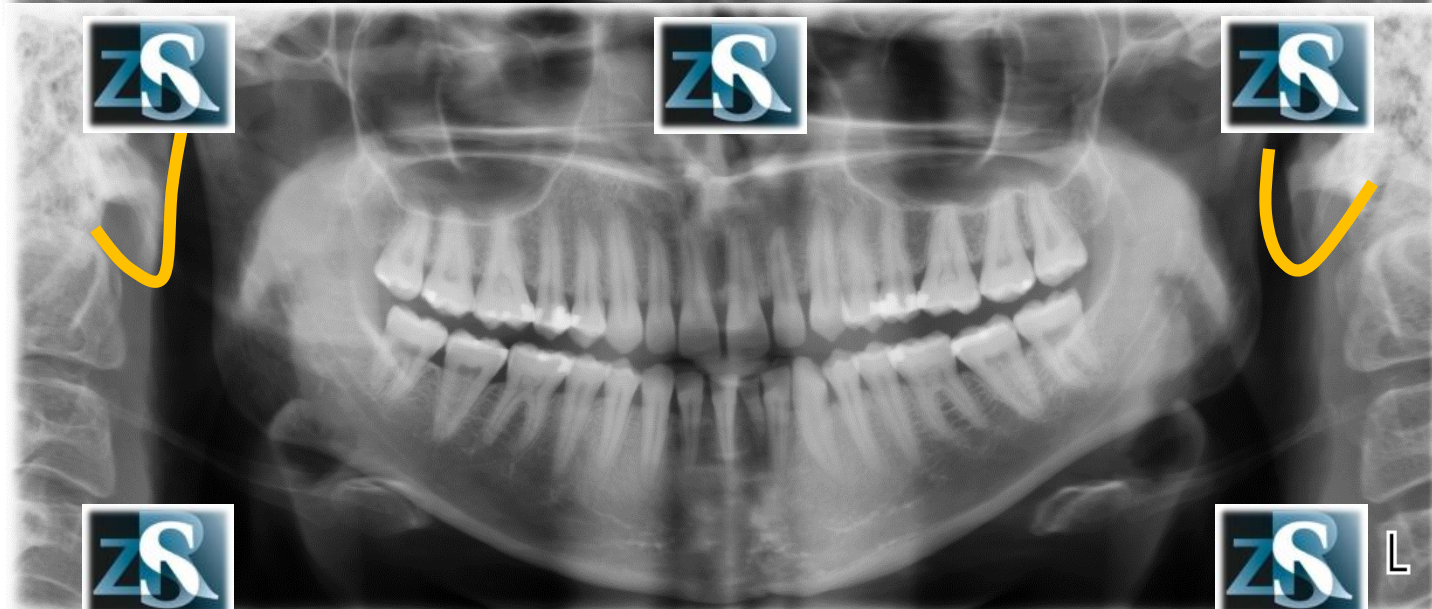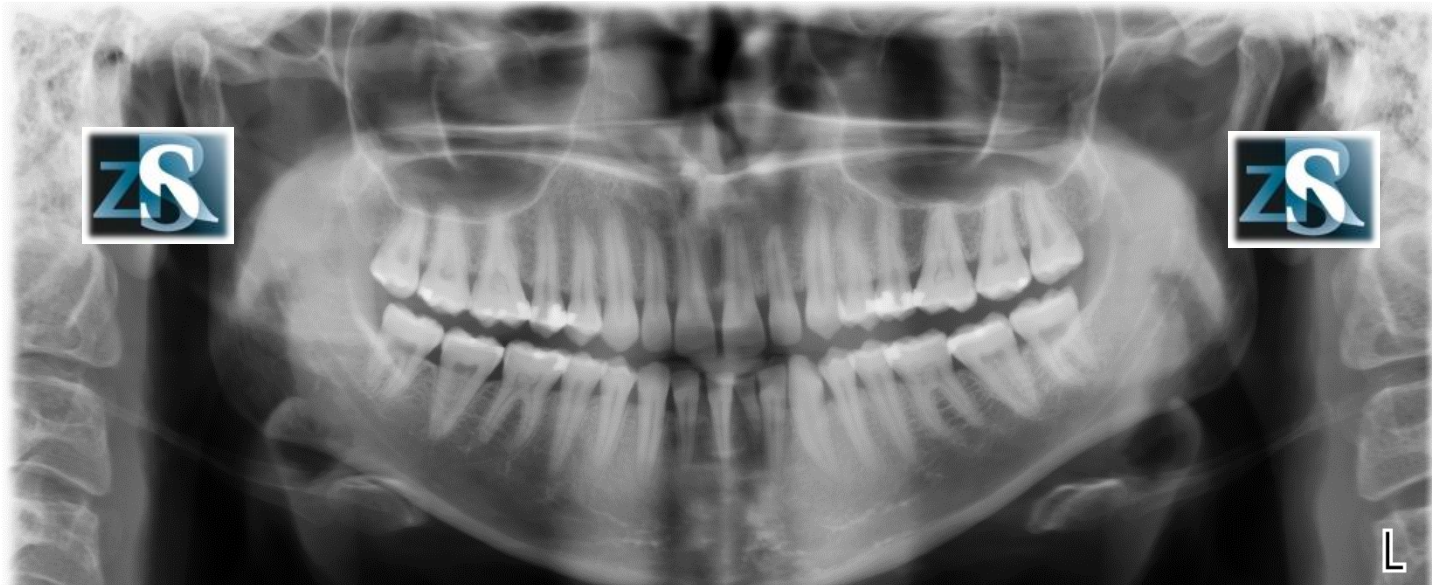
Kość gnykowa-rogi większe



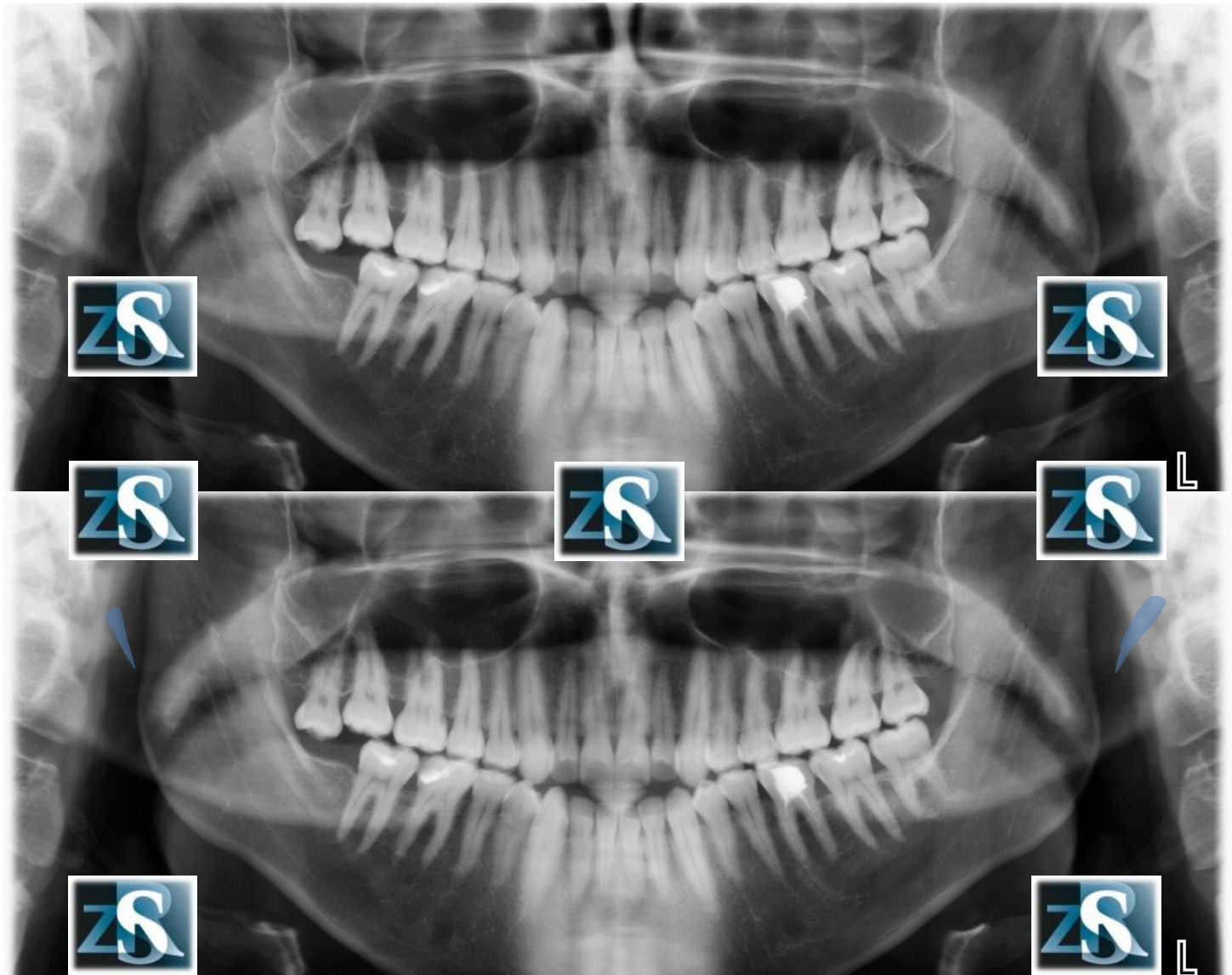Otwór słuchowy zewnętrzny



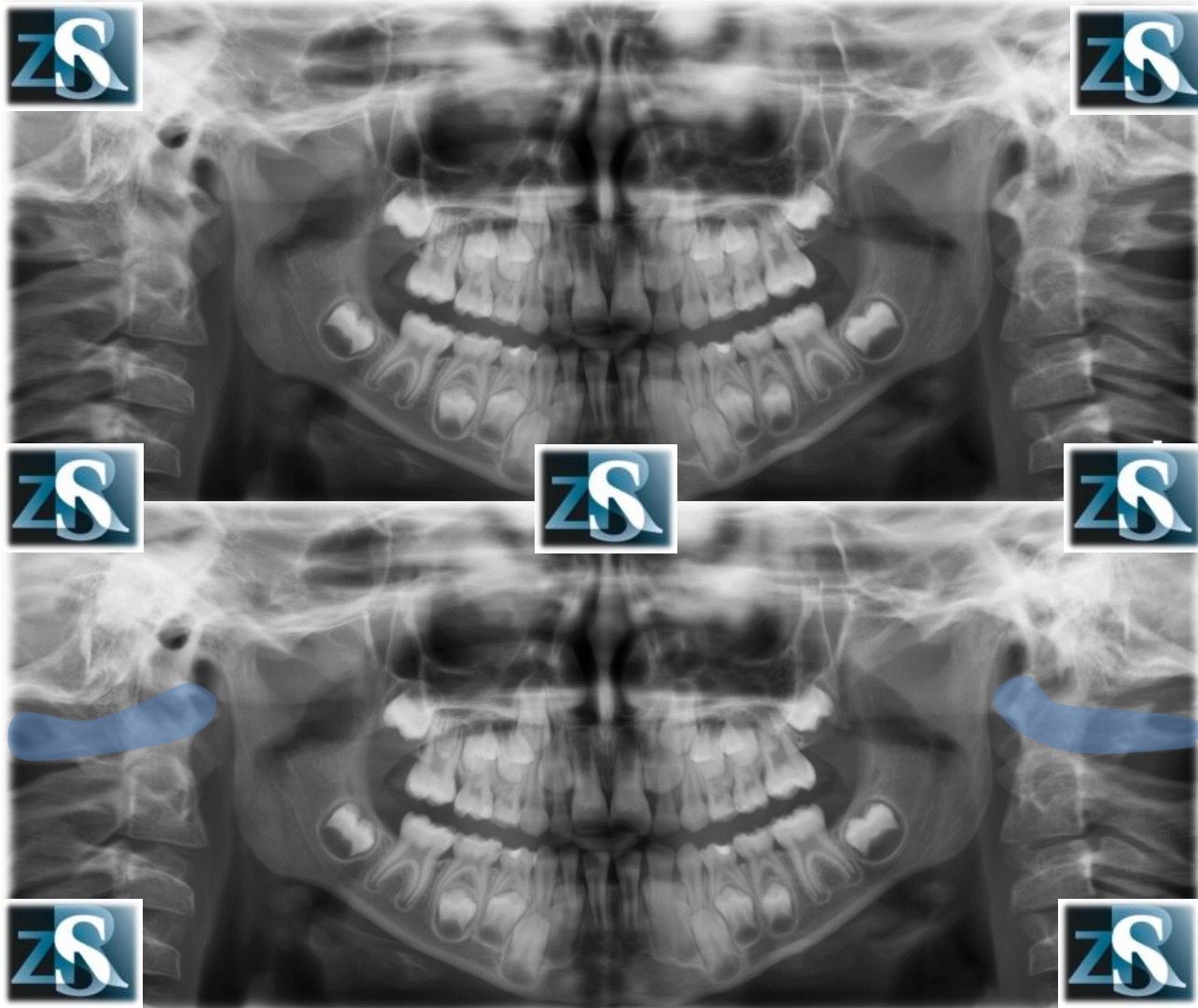
Płatki uszu



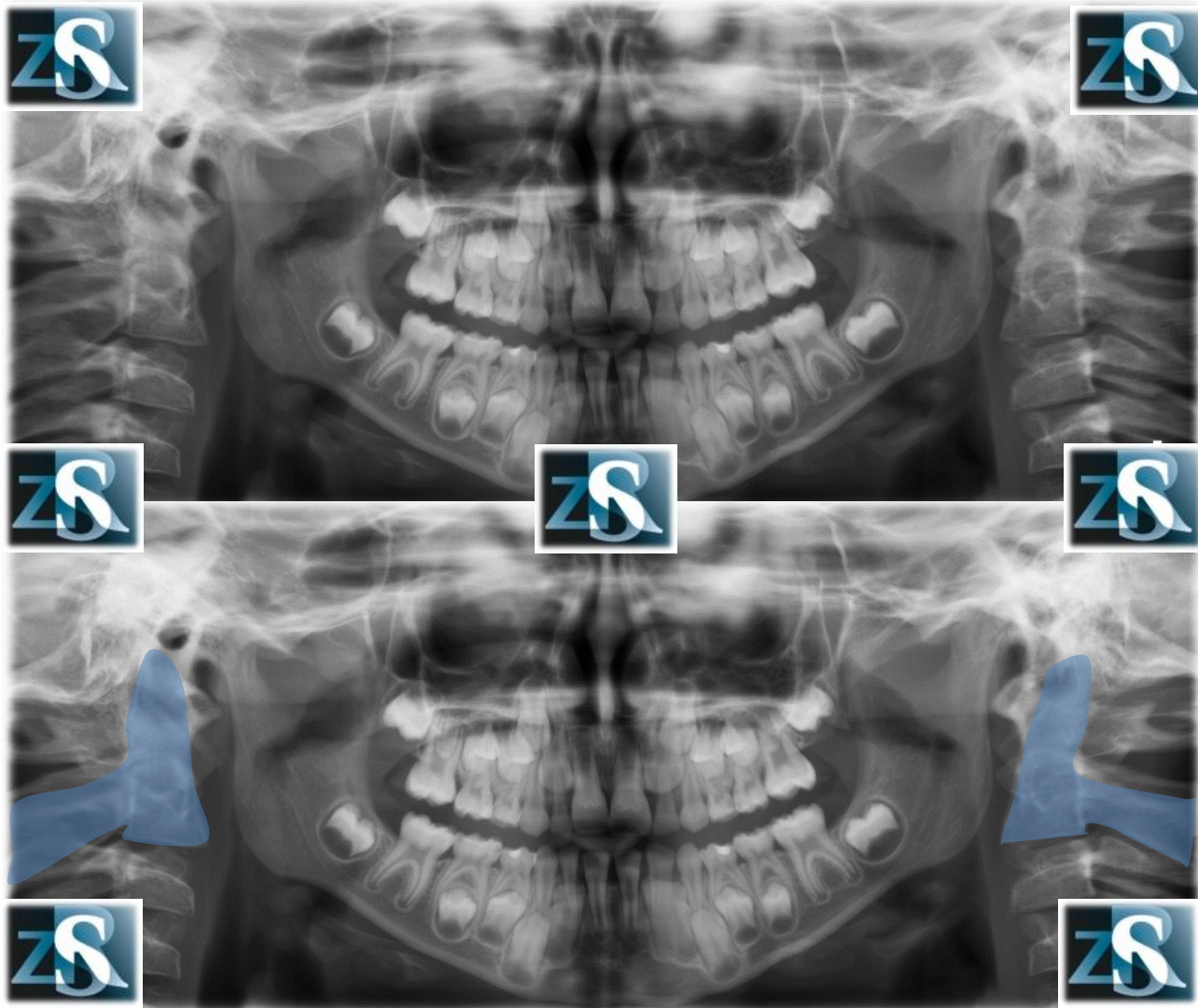
Wyrostek rylcowaty, zwapniałe więzadło rylcowo-zuchwowe i/lub więzadło rylcowo-gnykowe



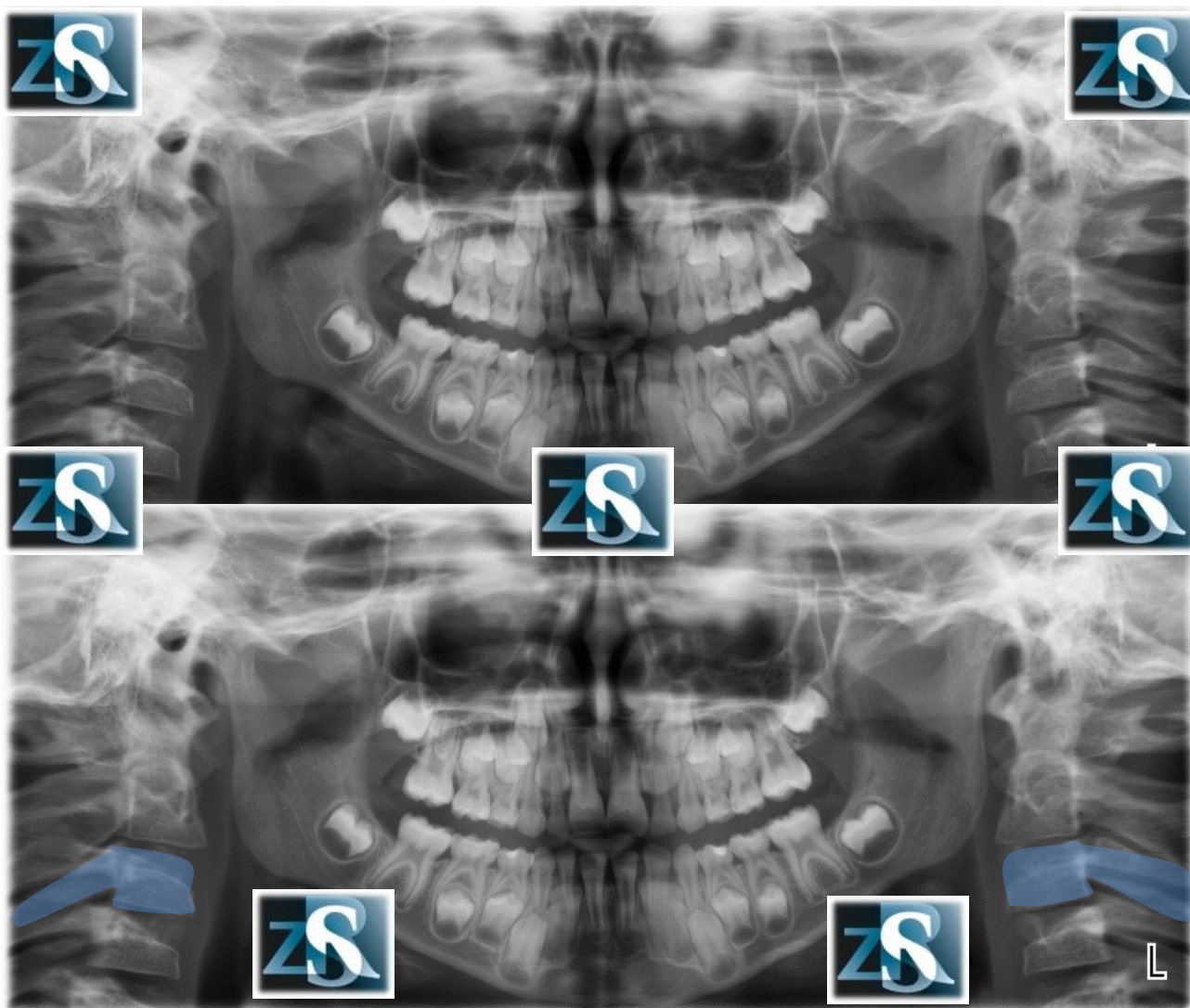
Krąg szczytowy (C1, atlas)



Kręgosłup szyjny (C2, axis)



Kręgosłup szyjny (C3)



Kręgosłup szyjny (C4)

