



# Pantomography: radiologic anatomy

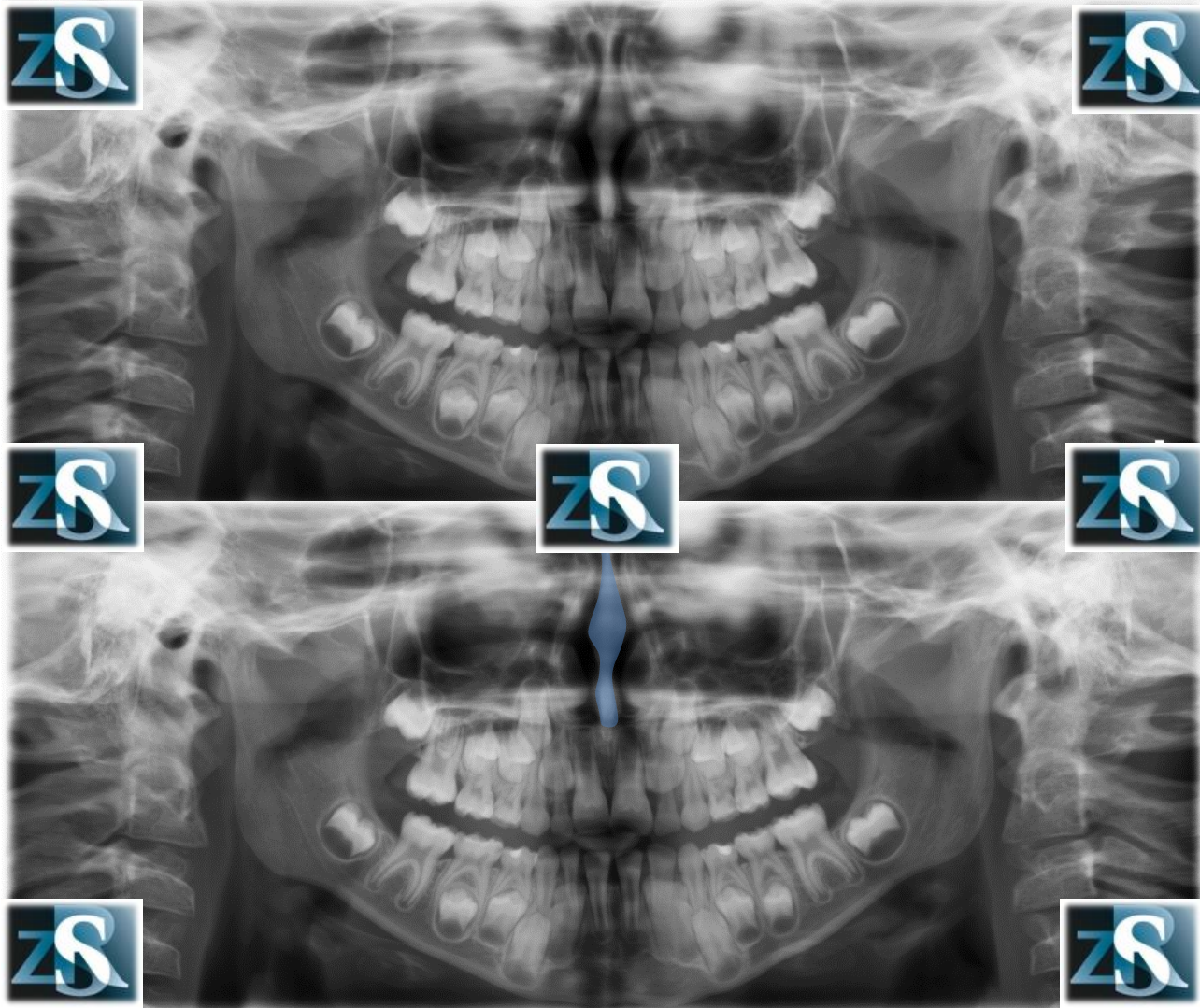
Kazimierz Szopiński

Department of Dental and Maxillofacial Radiology

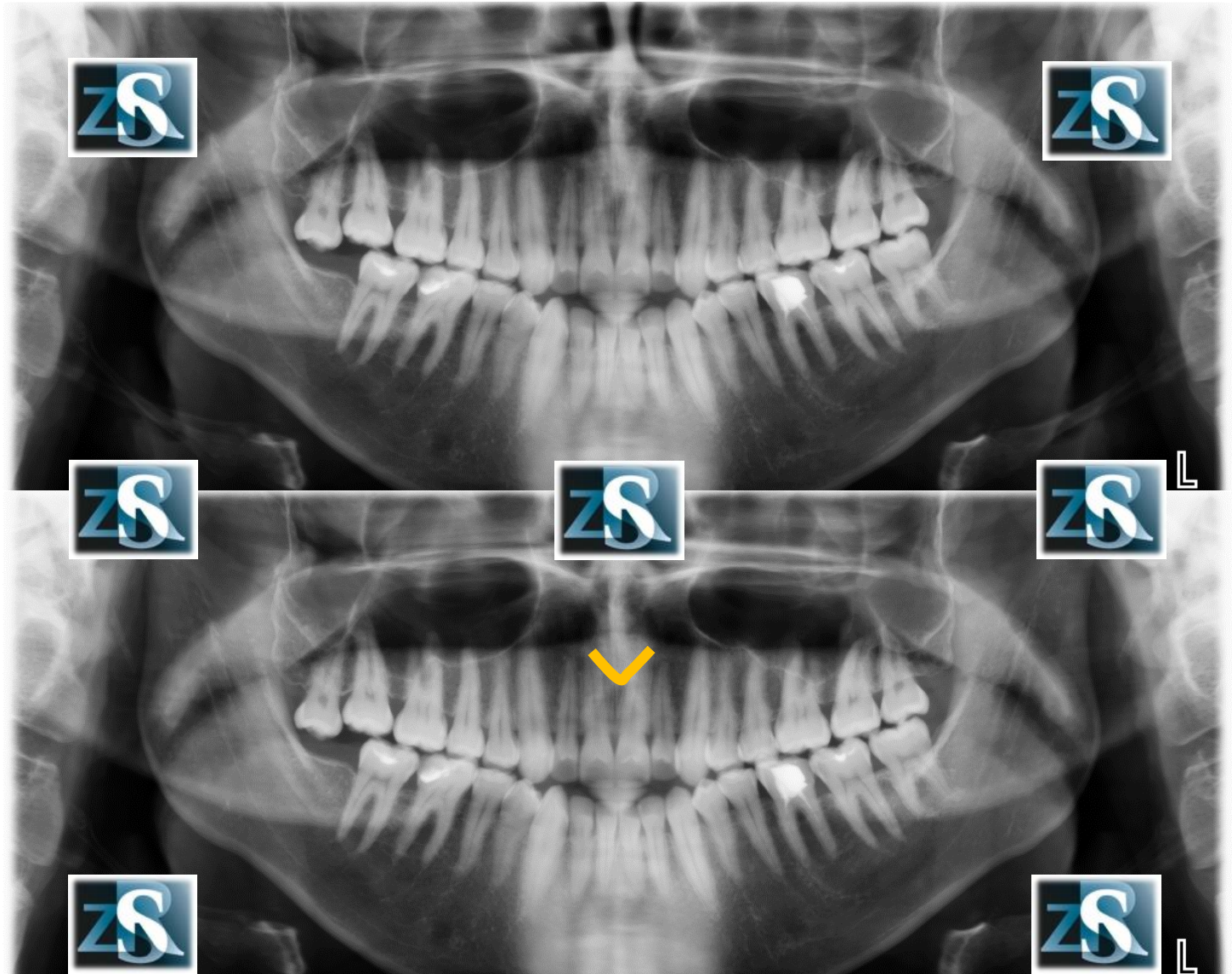
Faculty of Medicine and Dentistry

Medical University of Warsaw

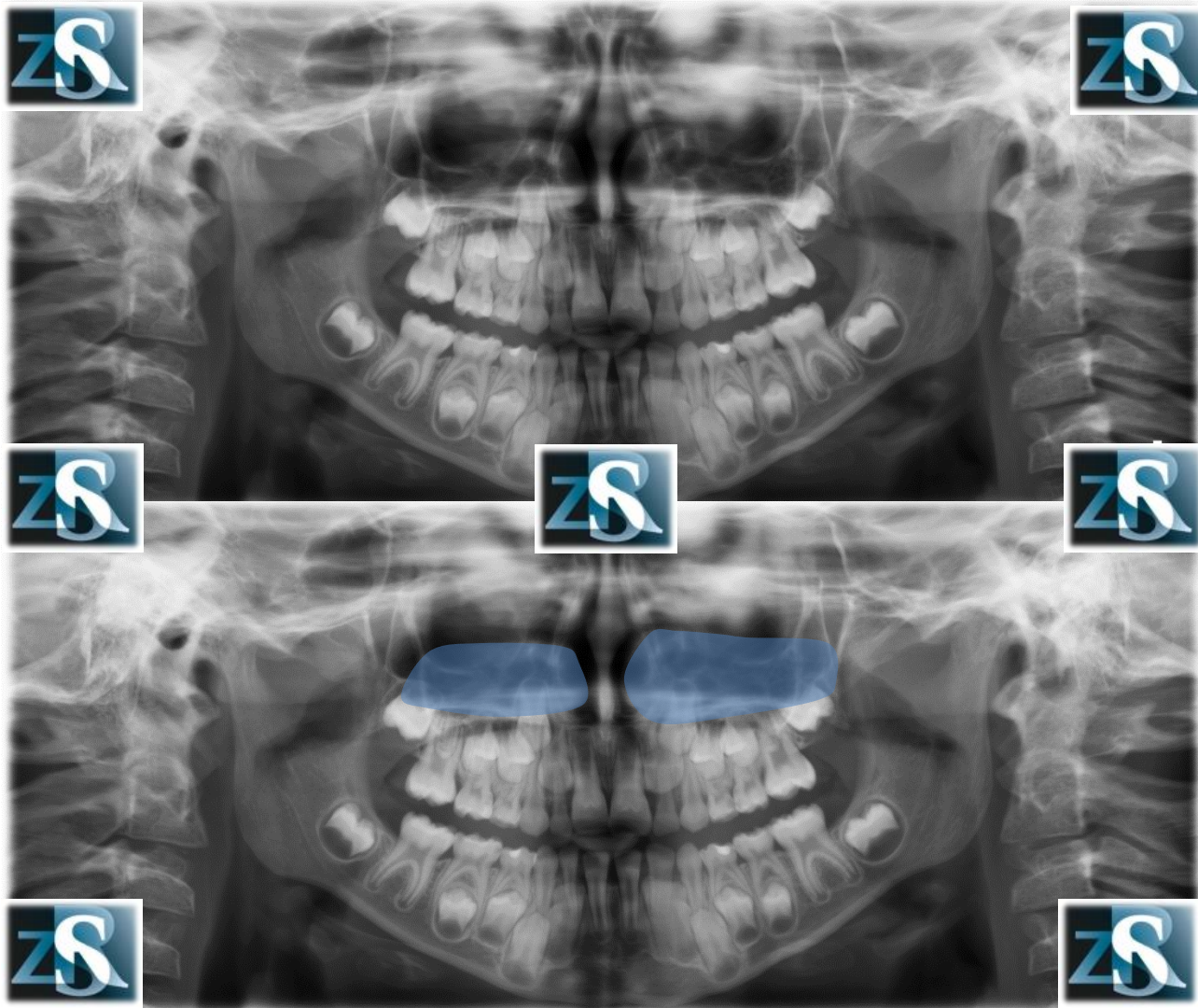
# Nasal septum



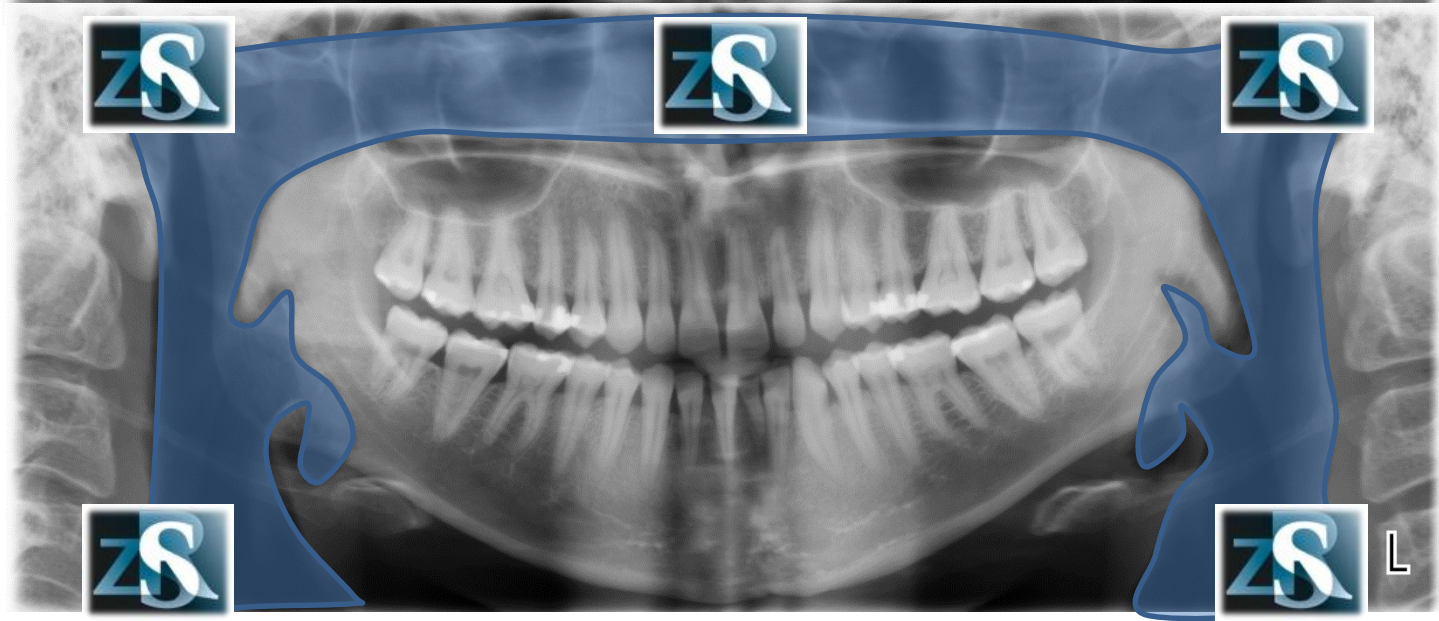
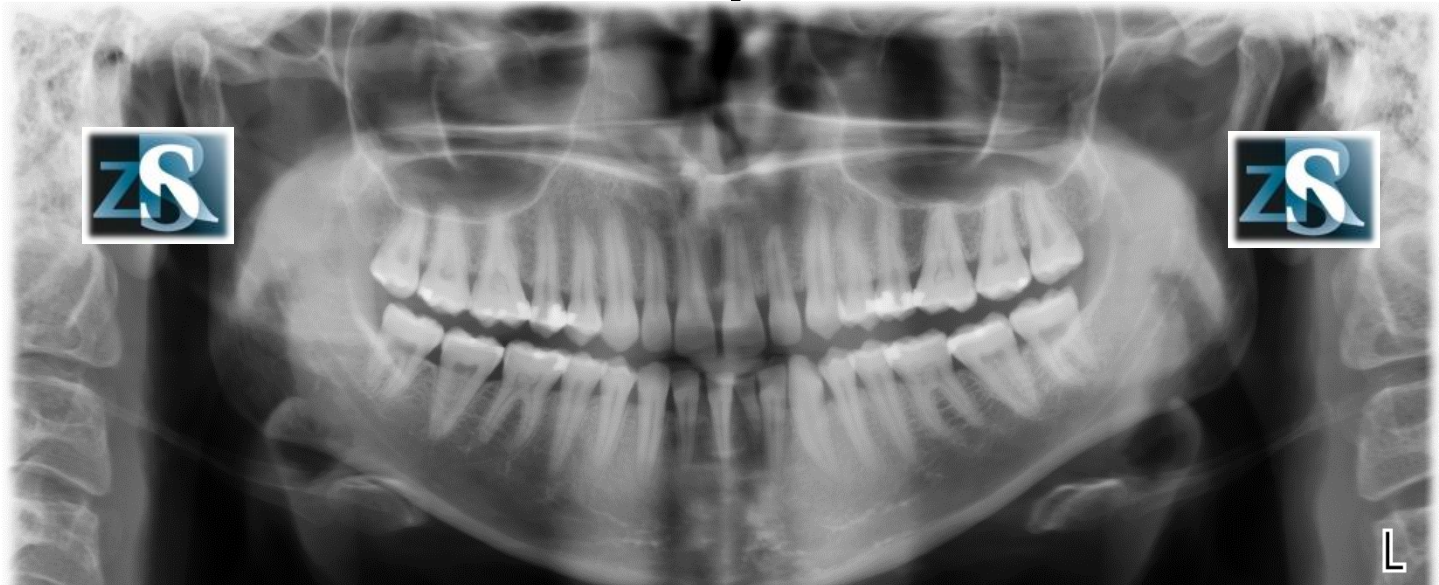
# Anterior nasal spine



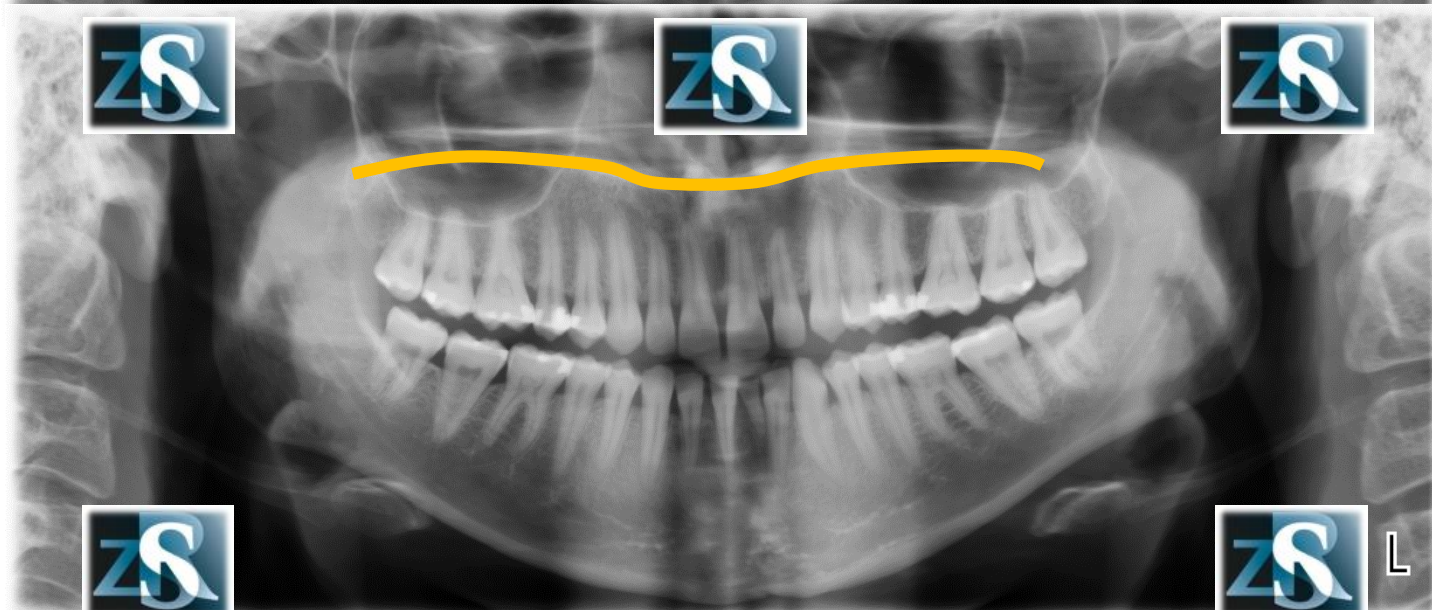
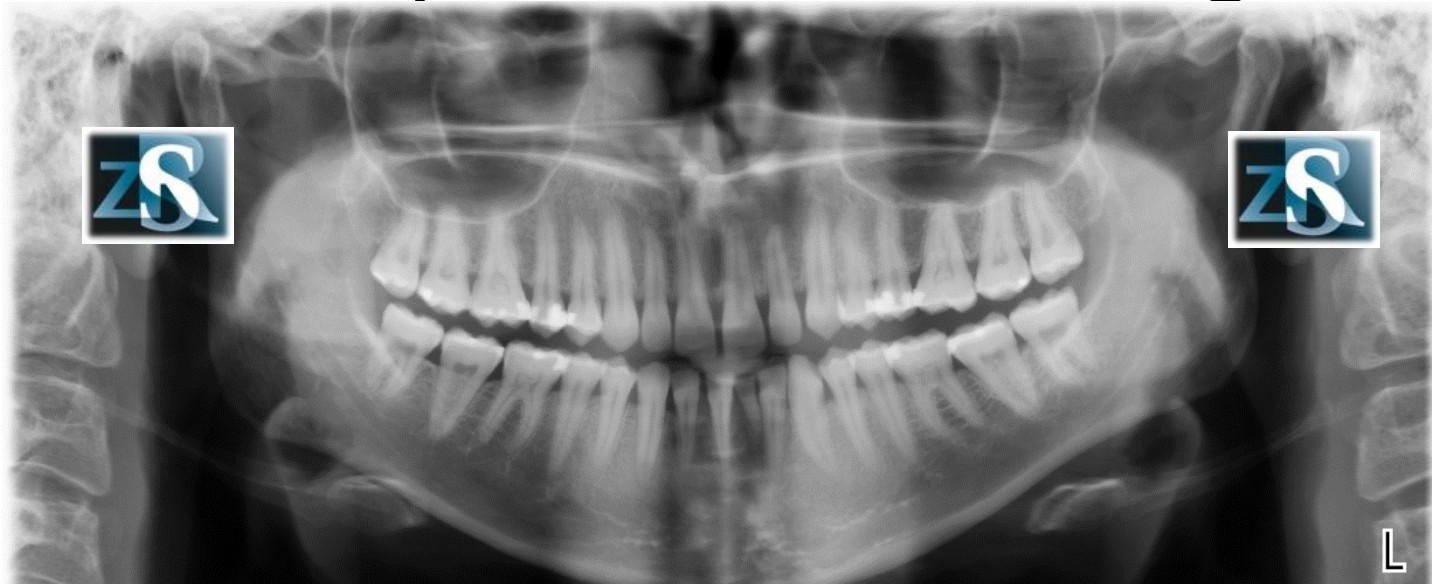
# Inferior nasal concha Inferior turbinate



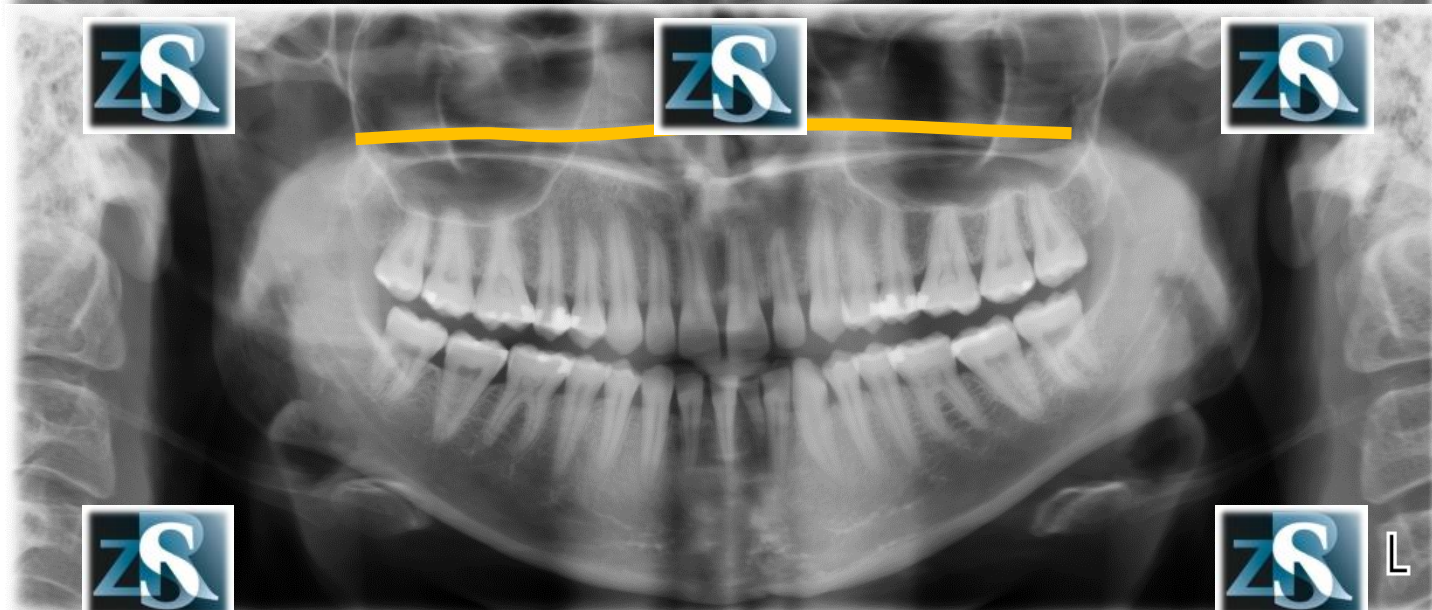
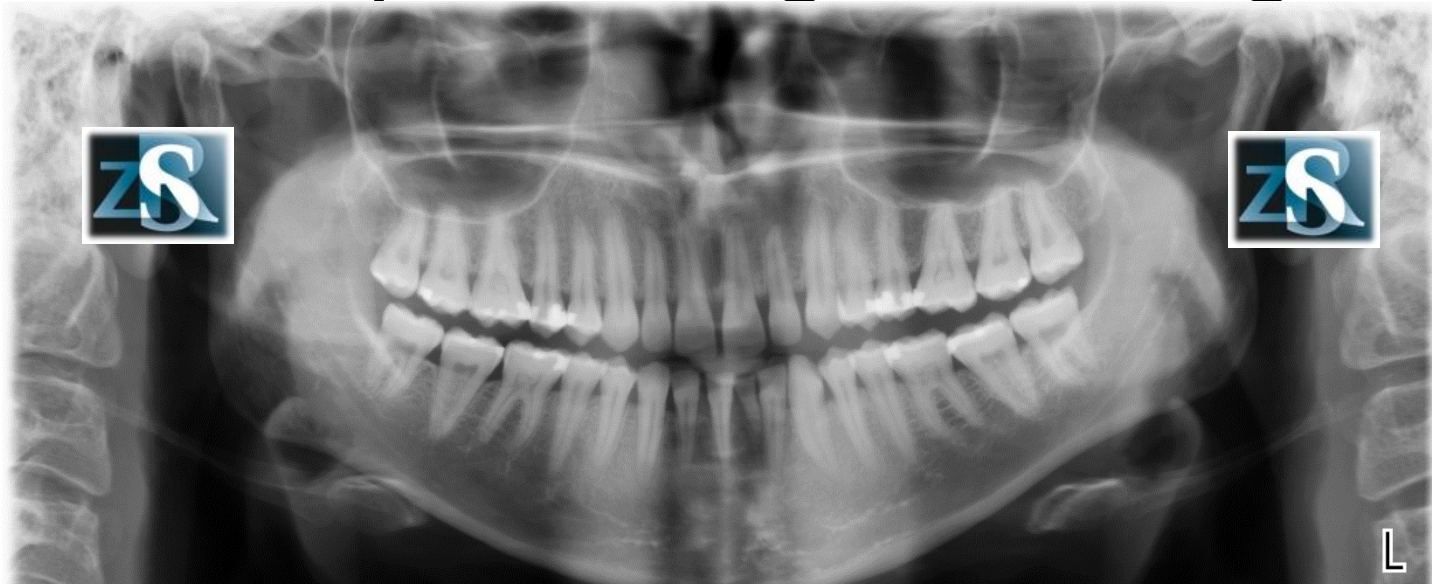
# Air space



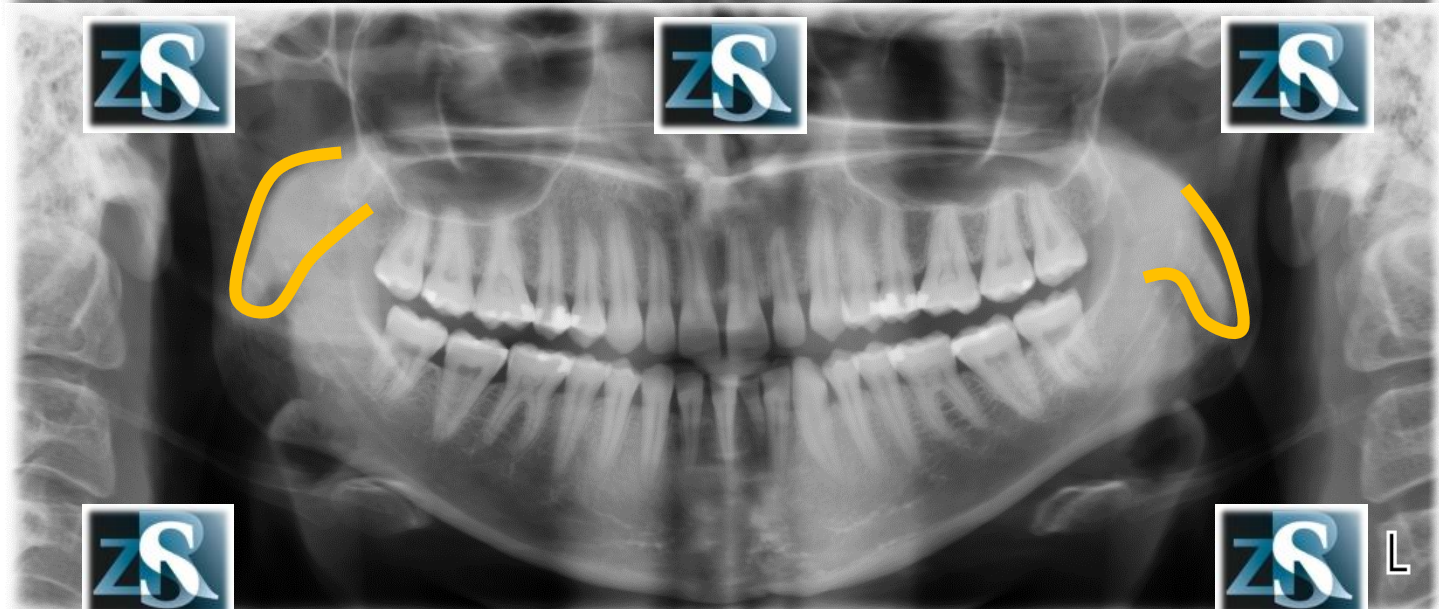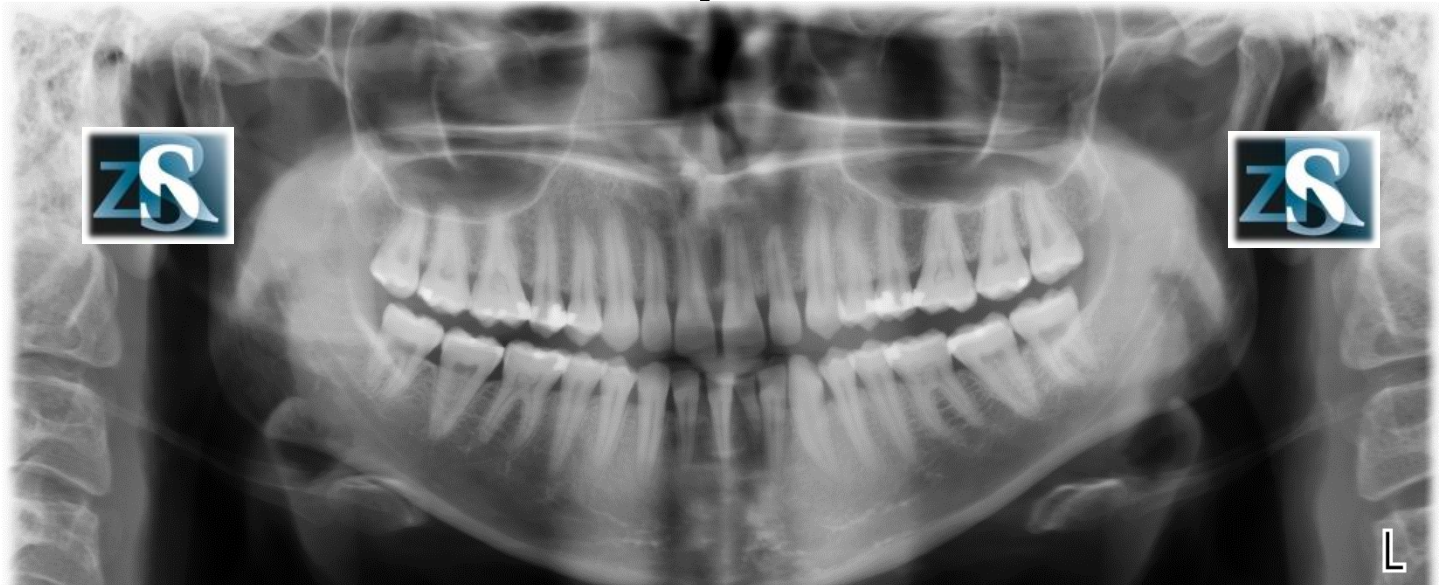
# Hard palate – real image



# Hard palate – ghost image

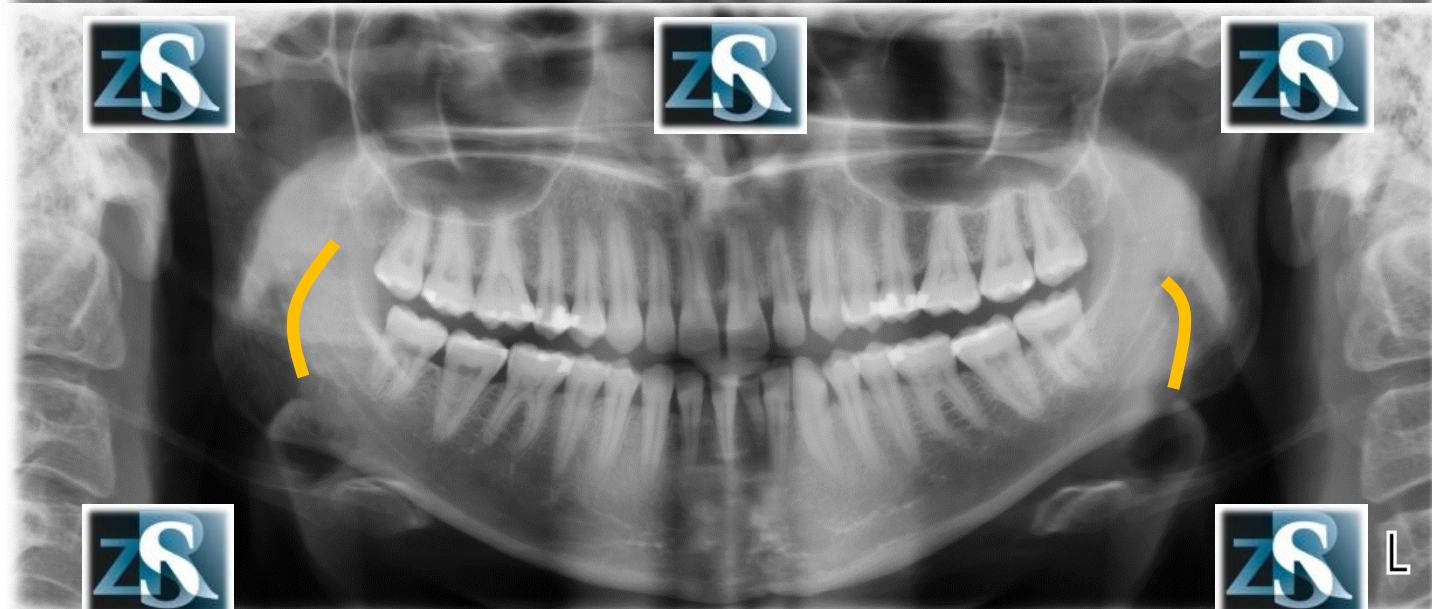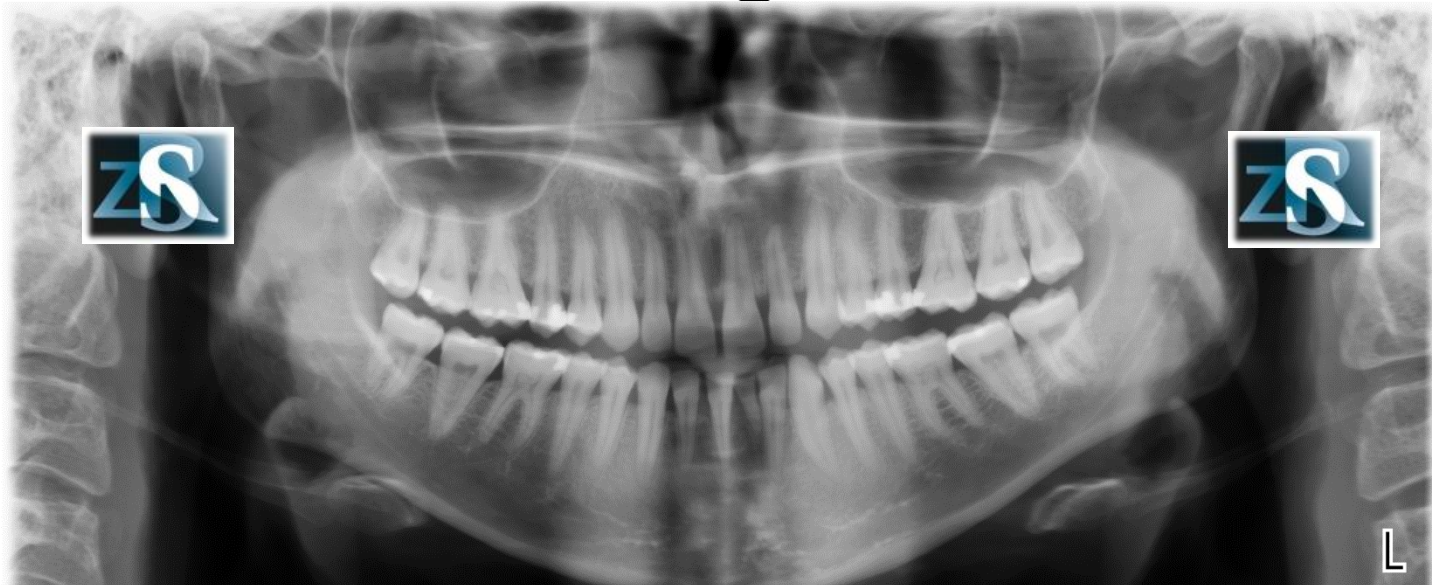


# Soft palate

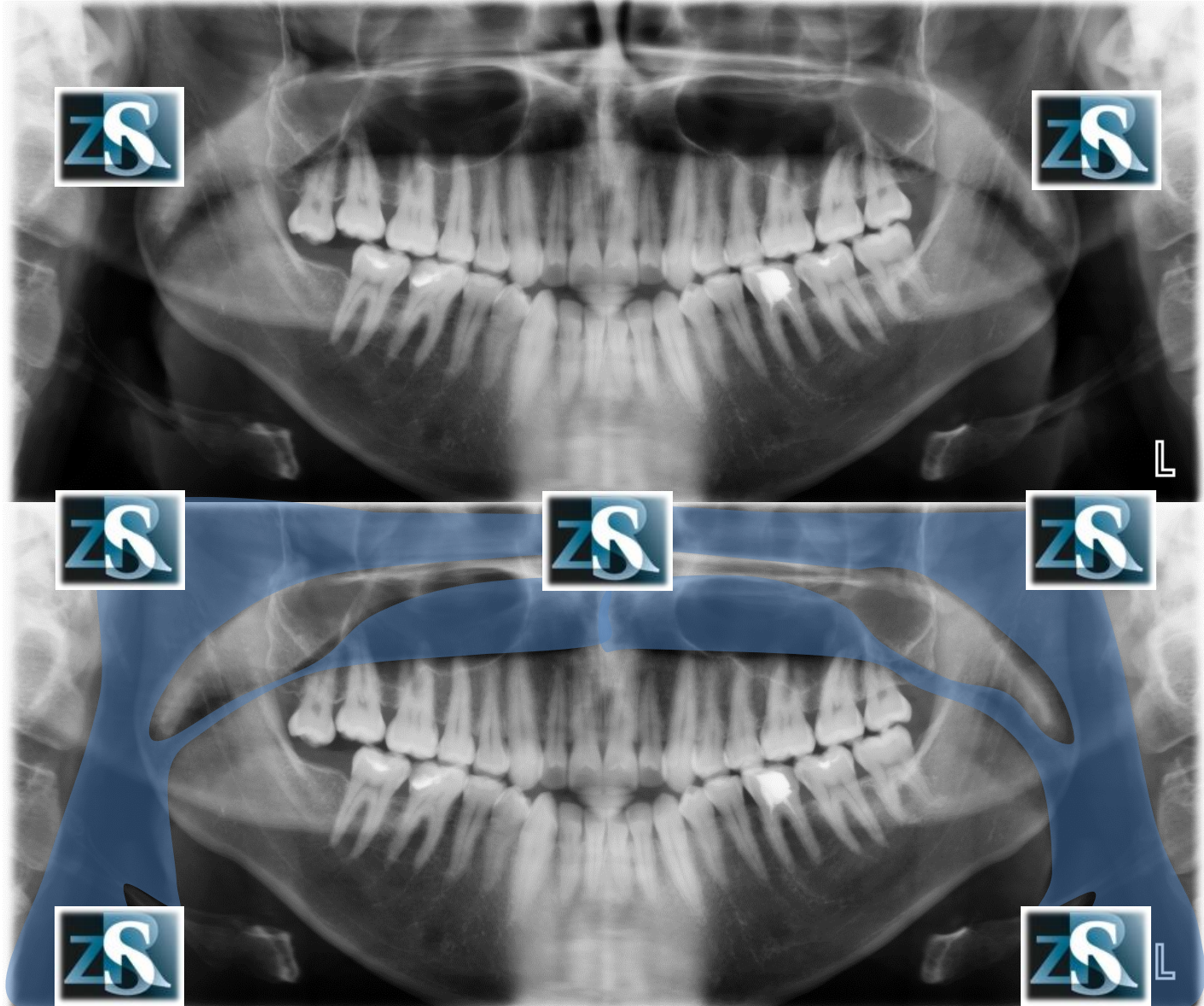




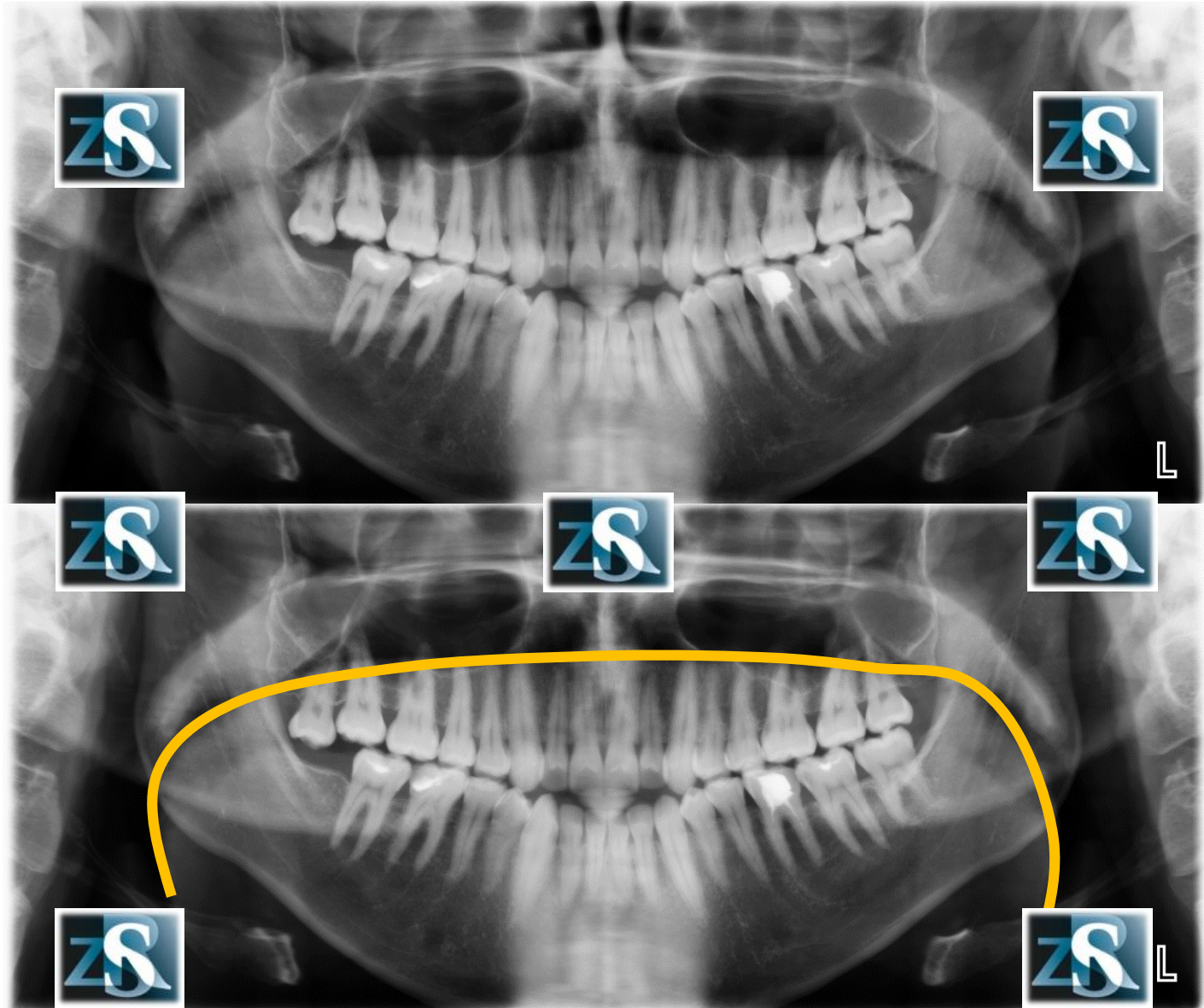
# Tongue



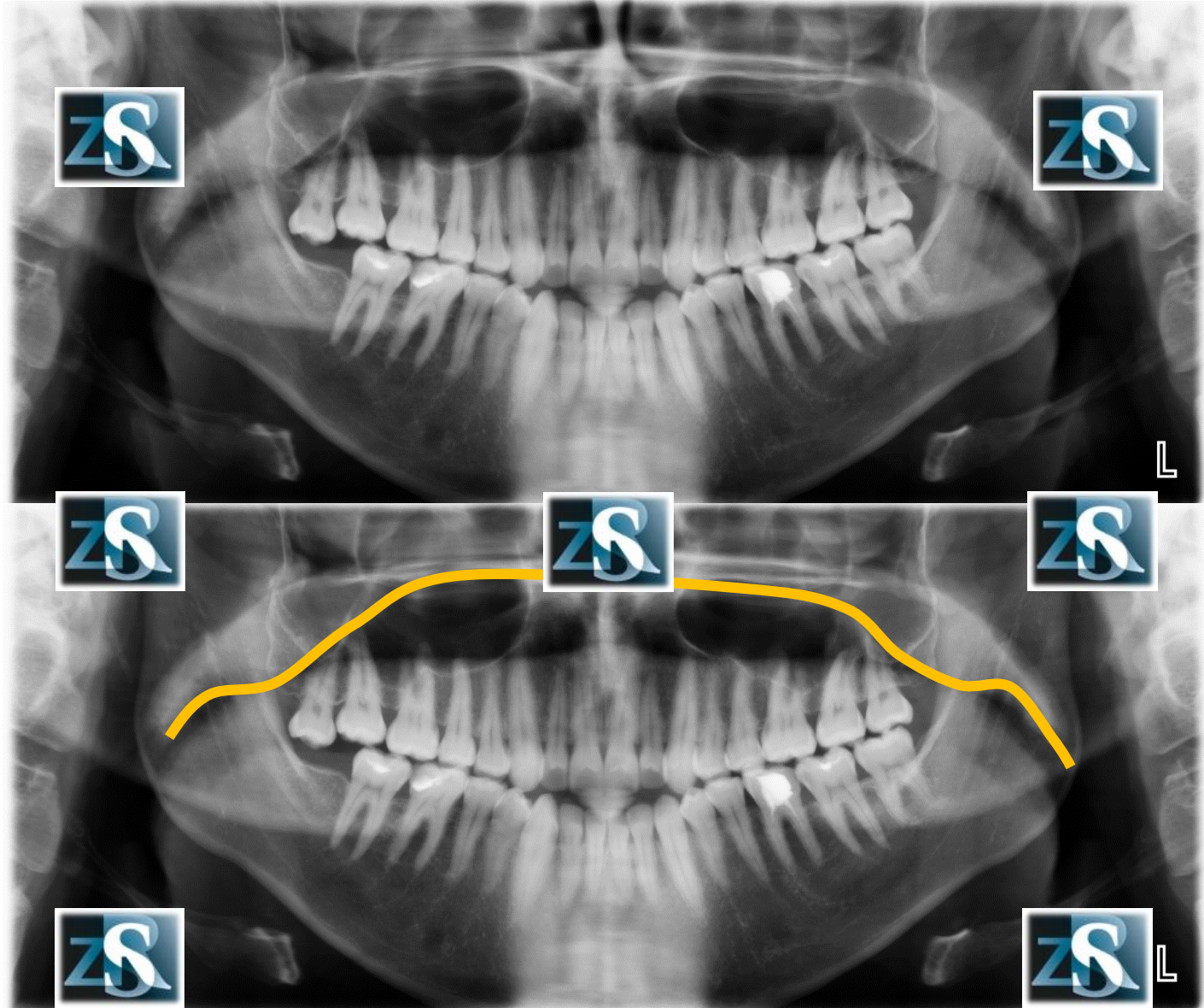
# Air space



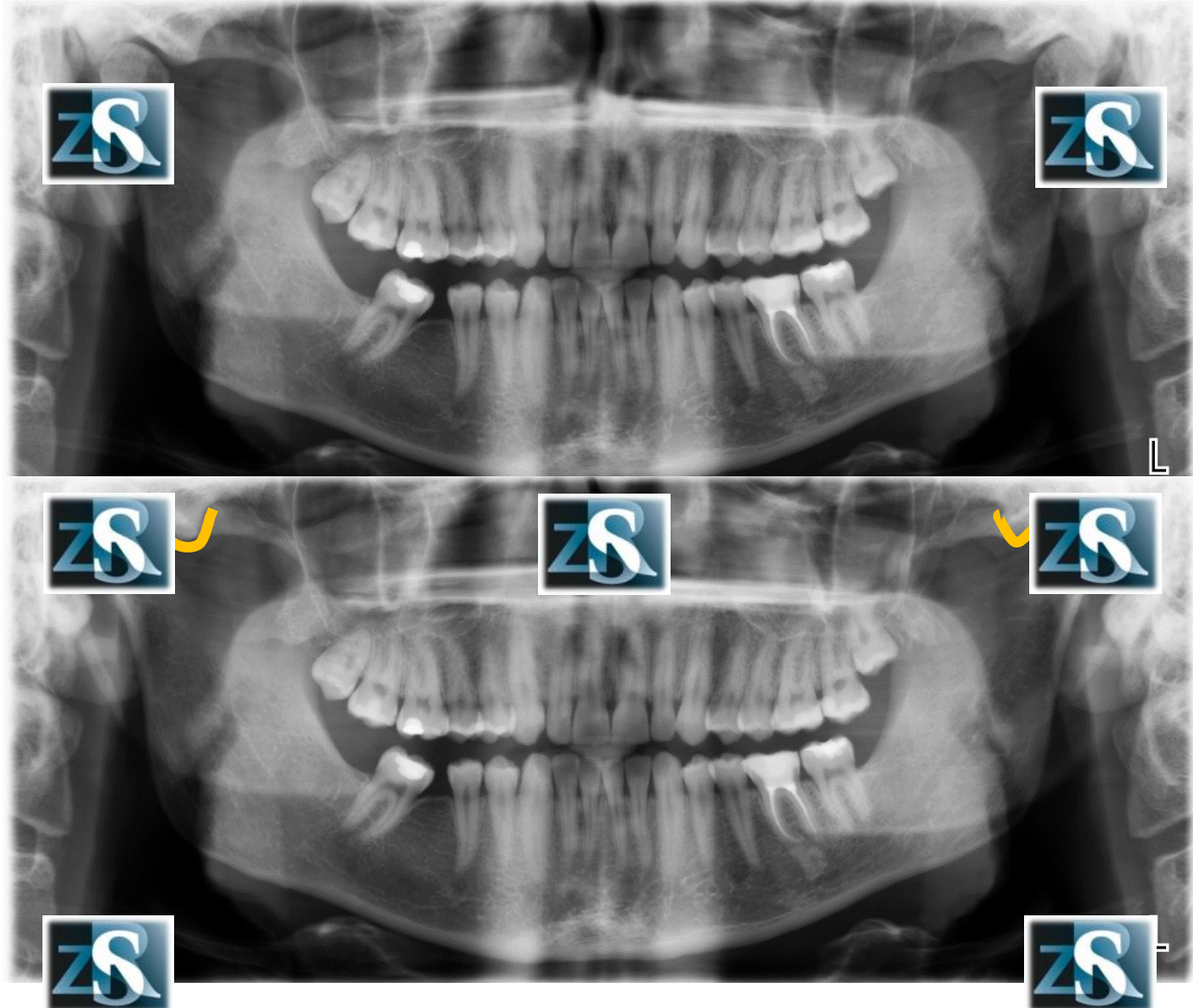
# Surface of the tongue



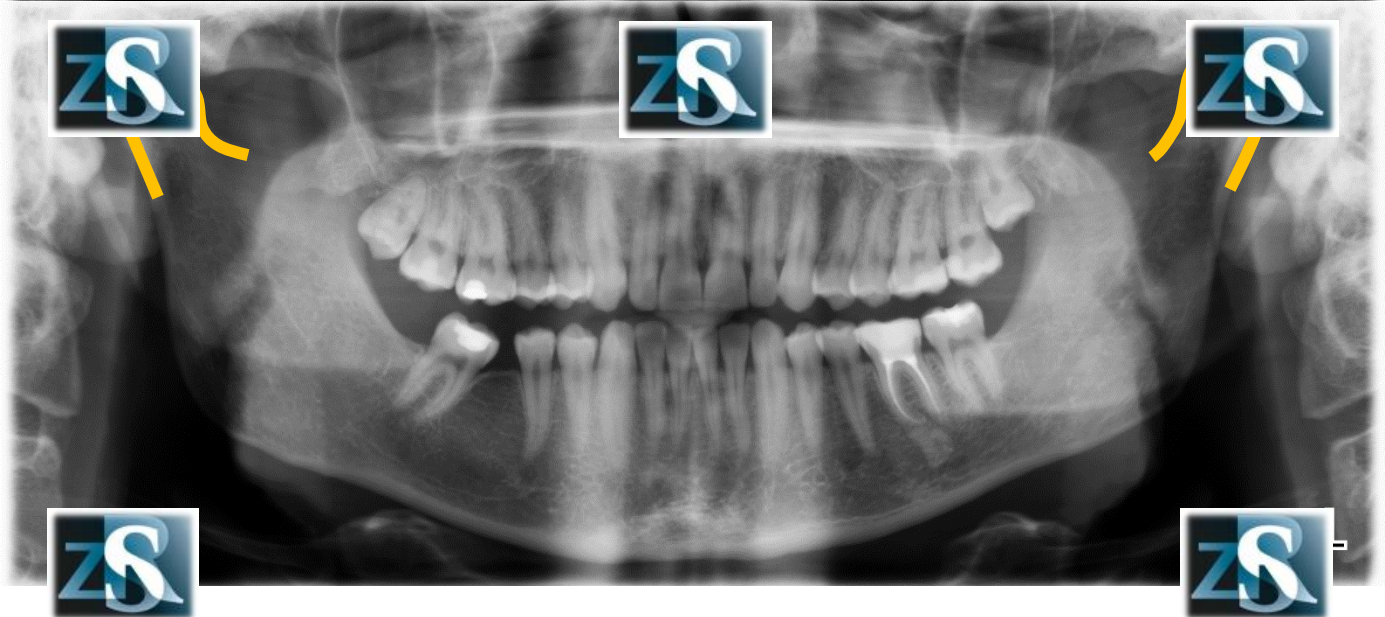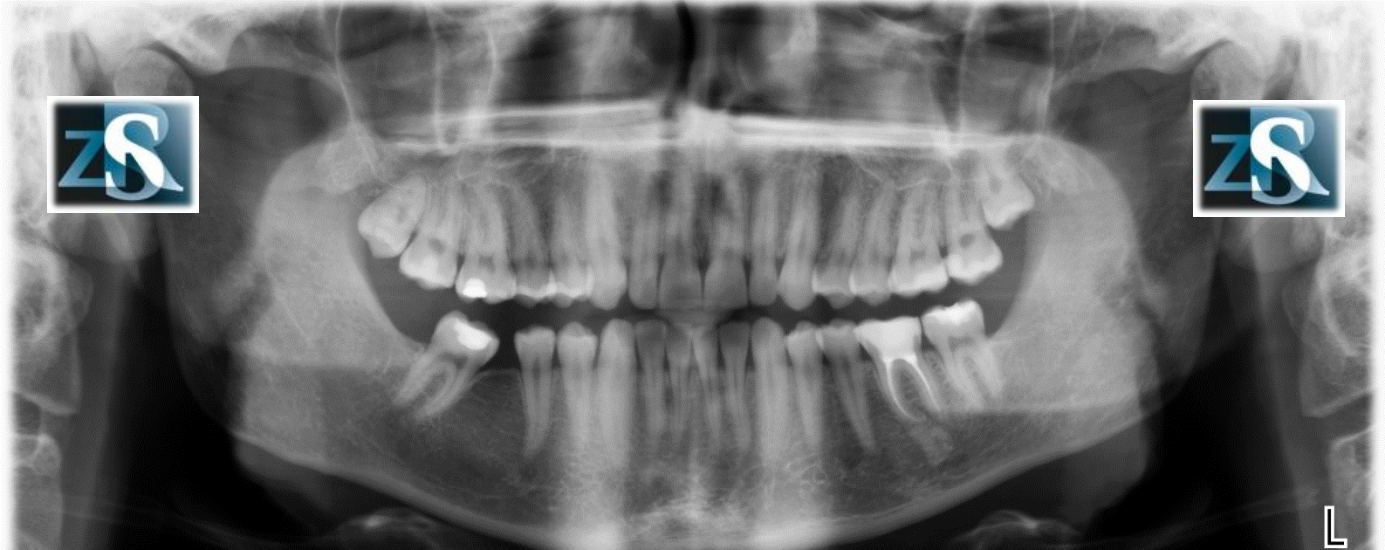# Surface of the palate



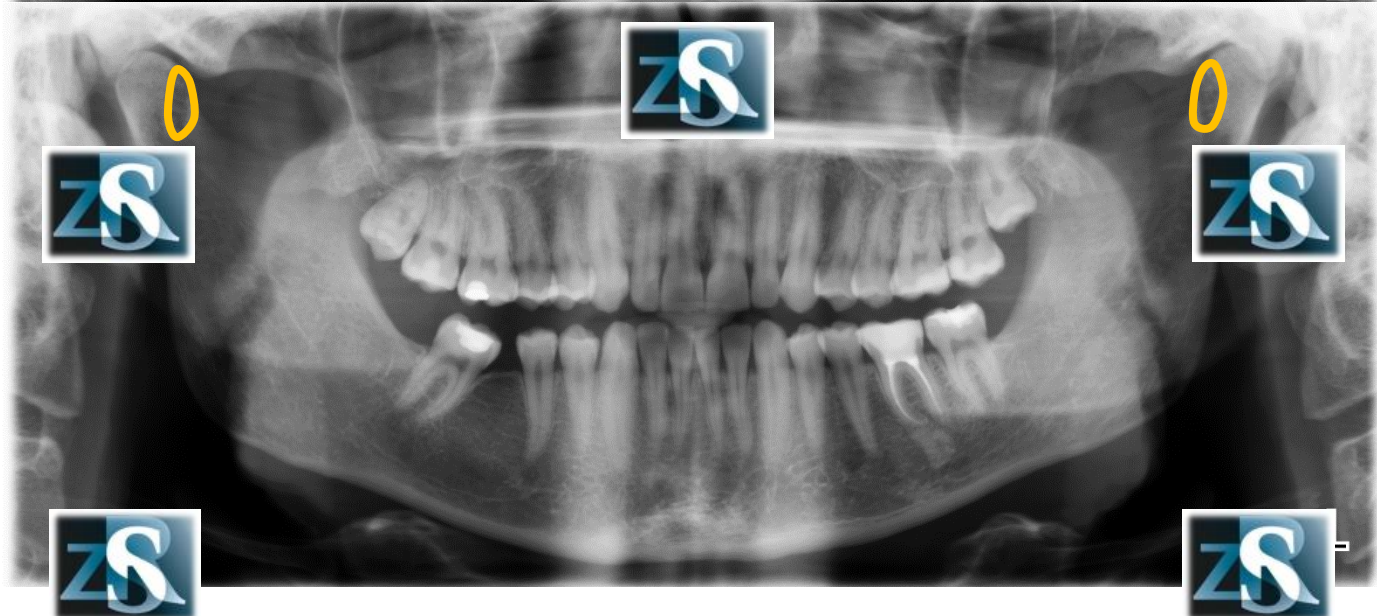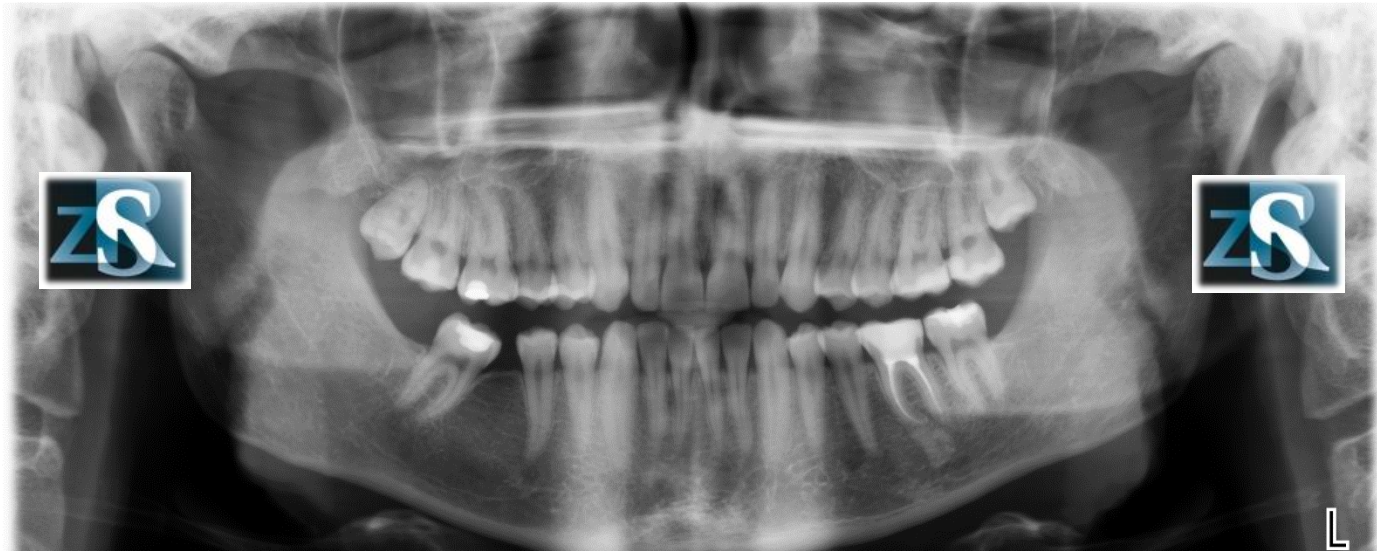# Articular eminence



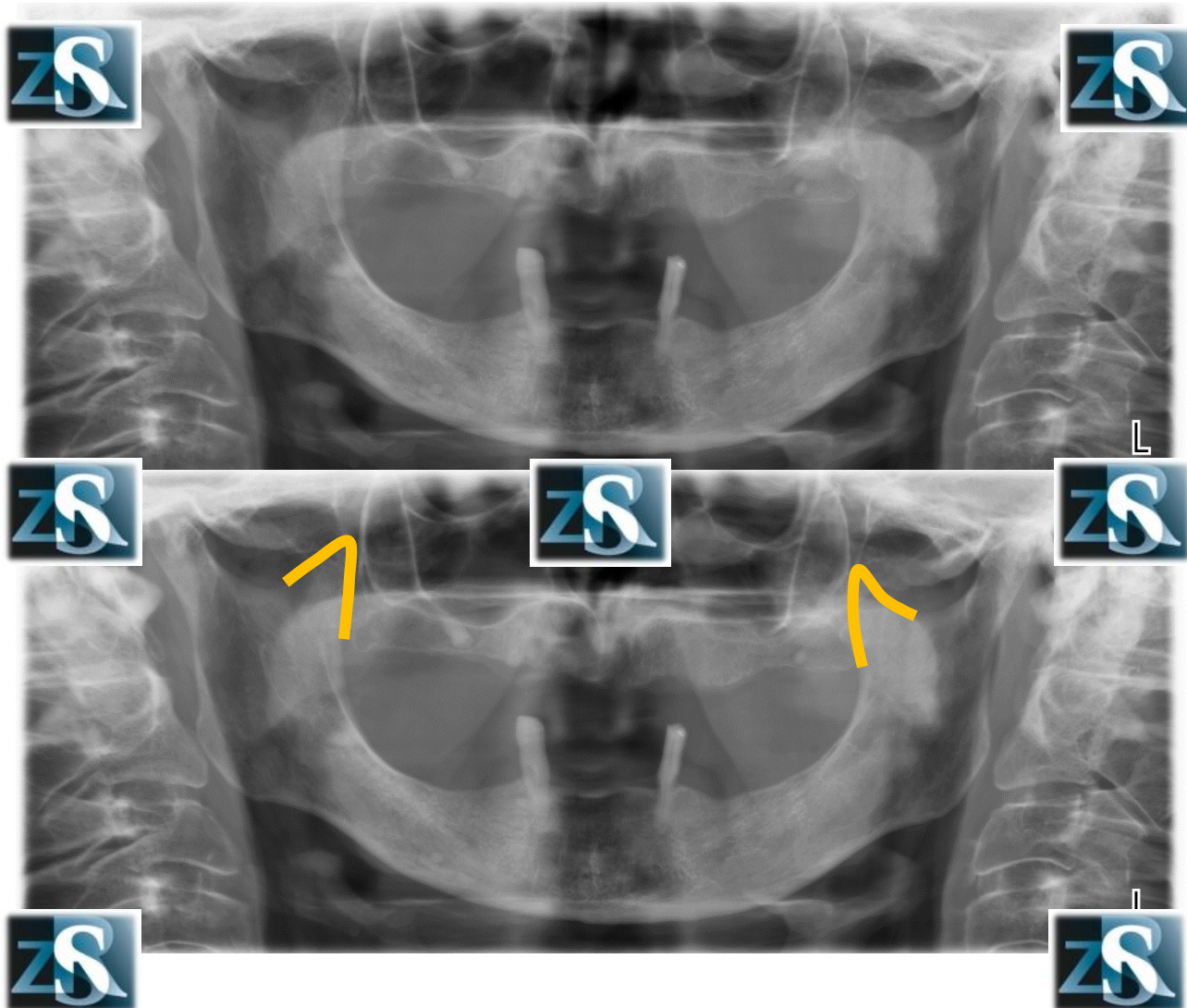
# Condyles



# Pterygoid fovea

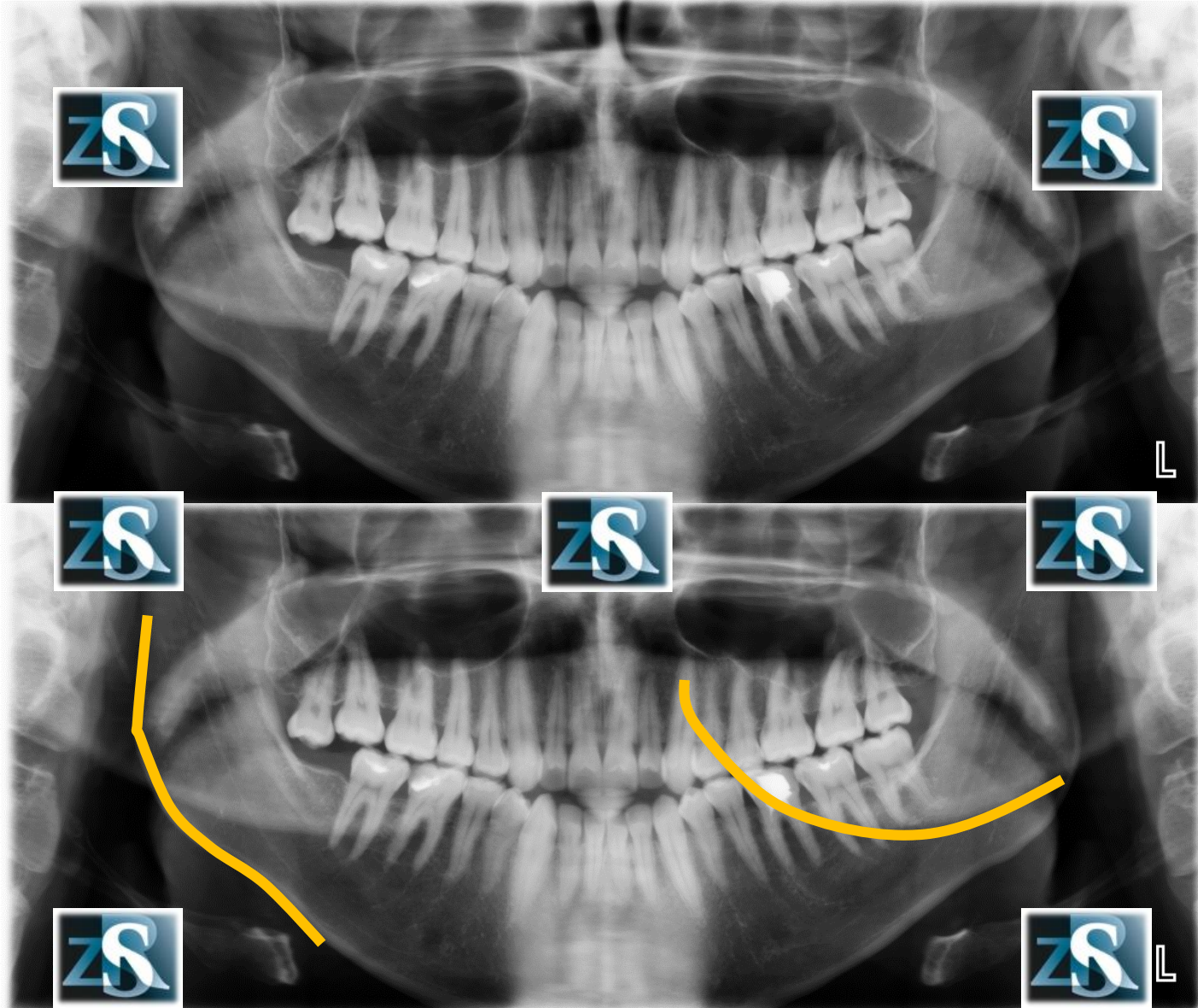


# Coronoid processes

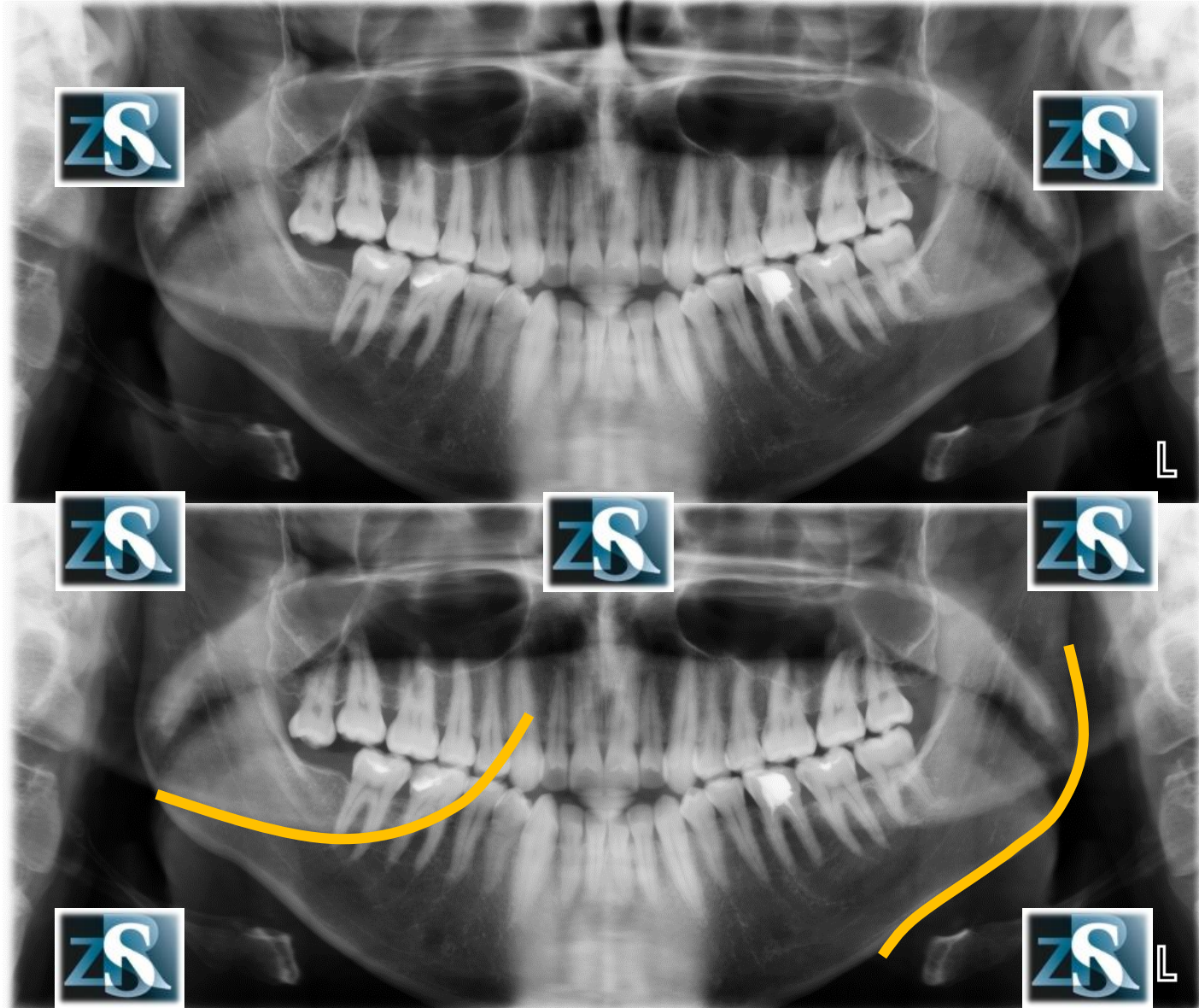




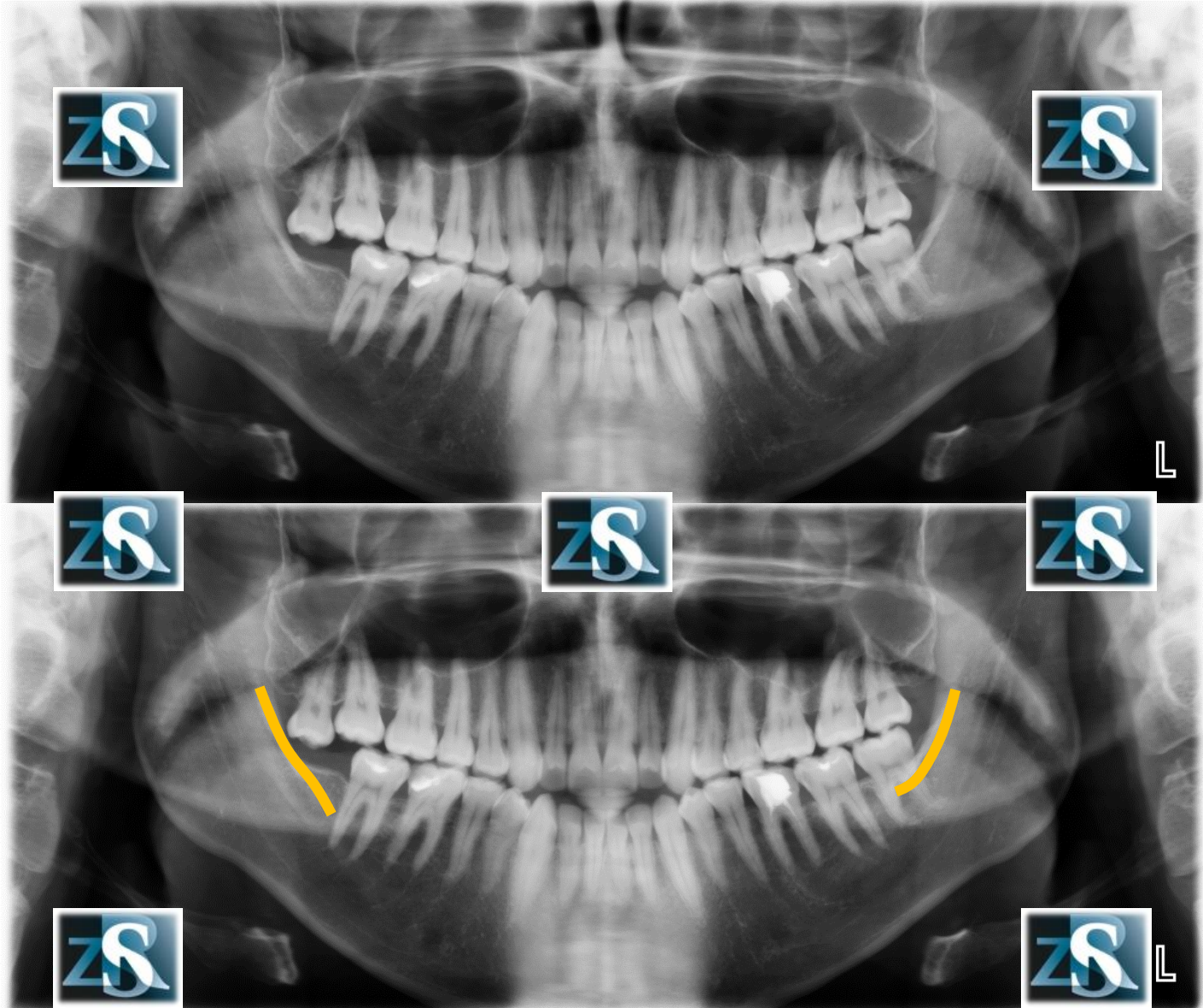
# Right angle of the mandible (real and ghost image)



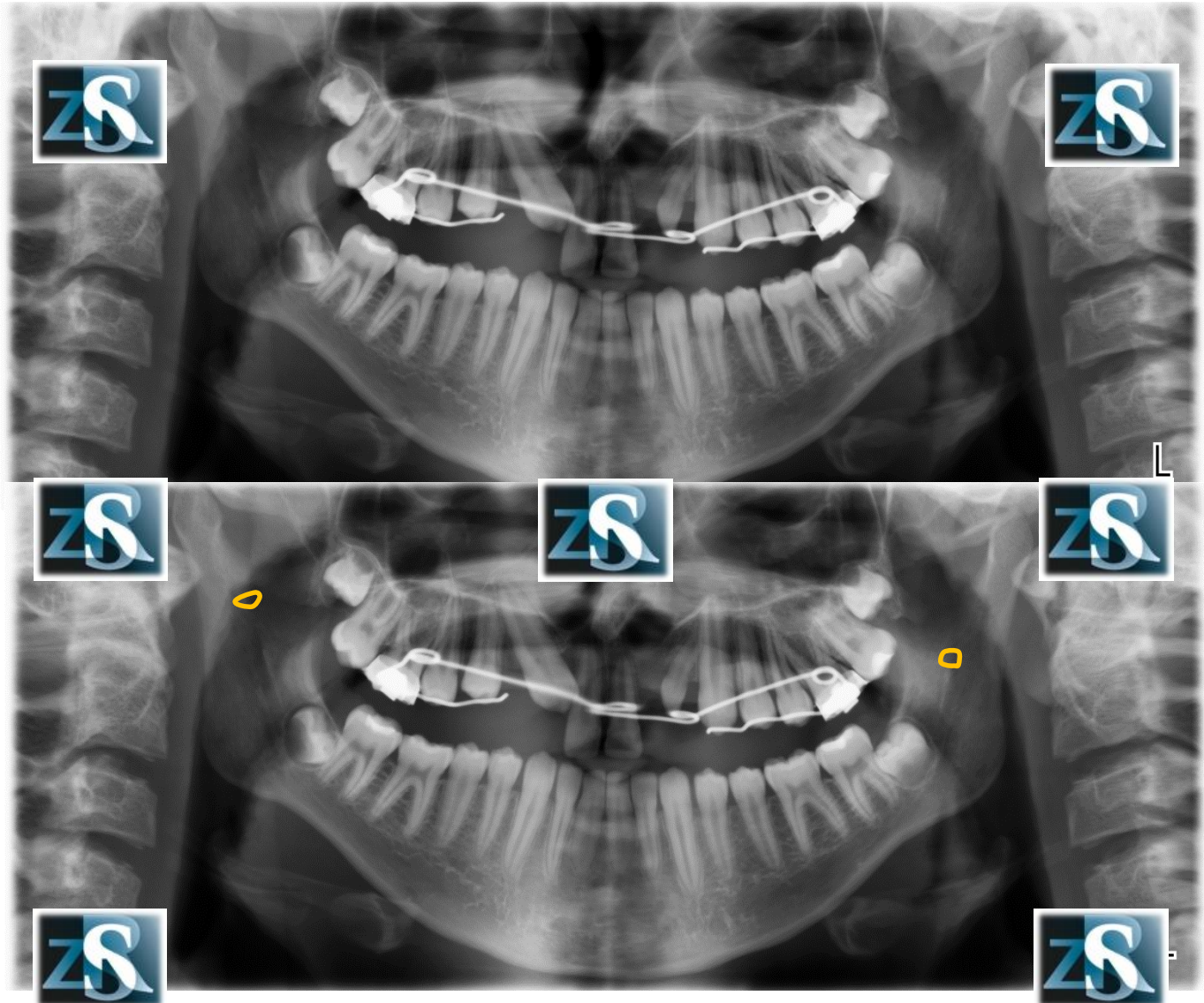
# Left angle of the mandible (real and ghost image)



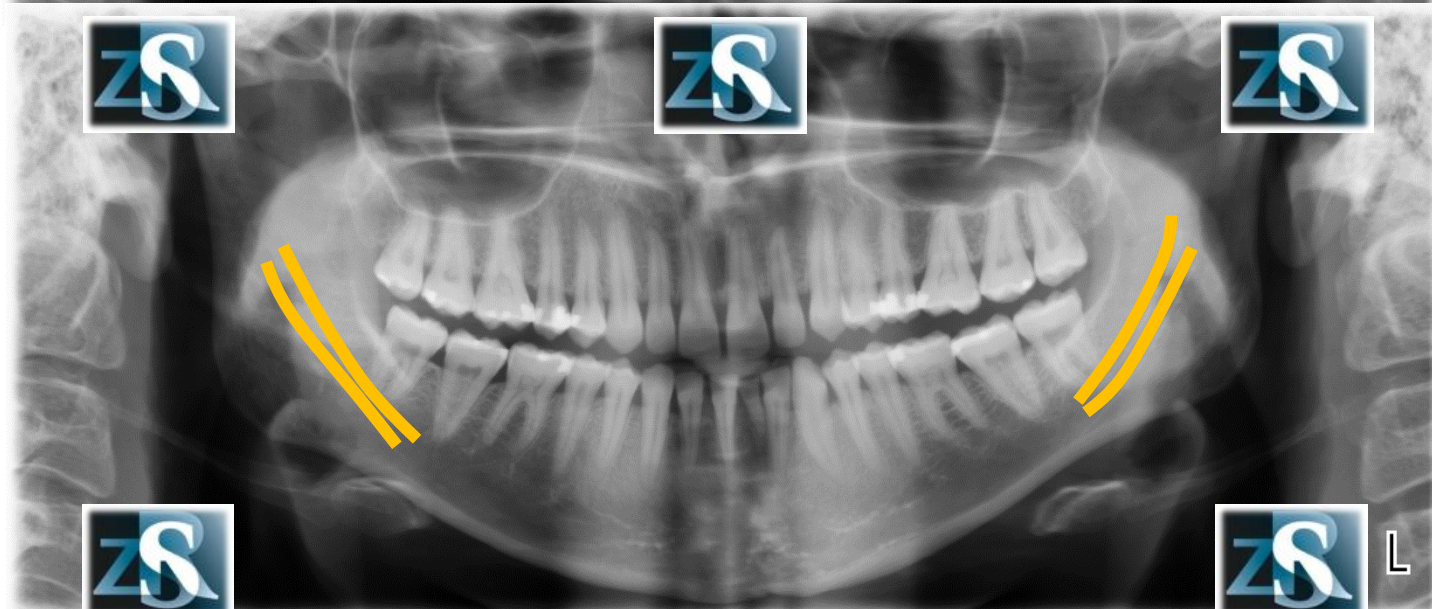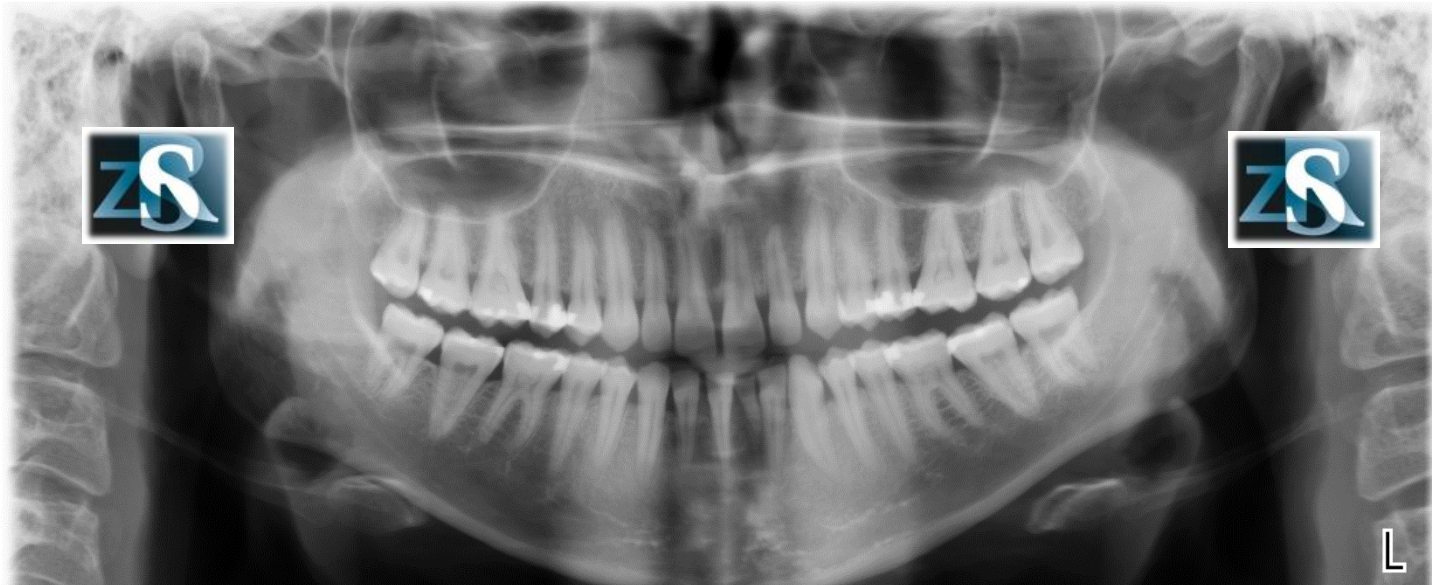
# Oblique line



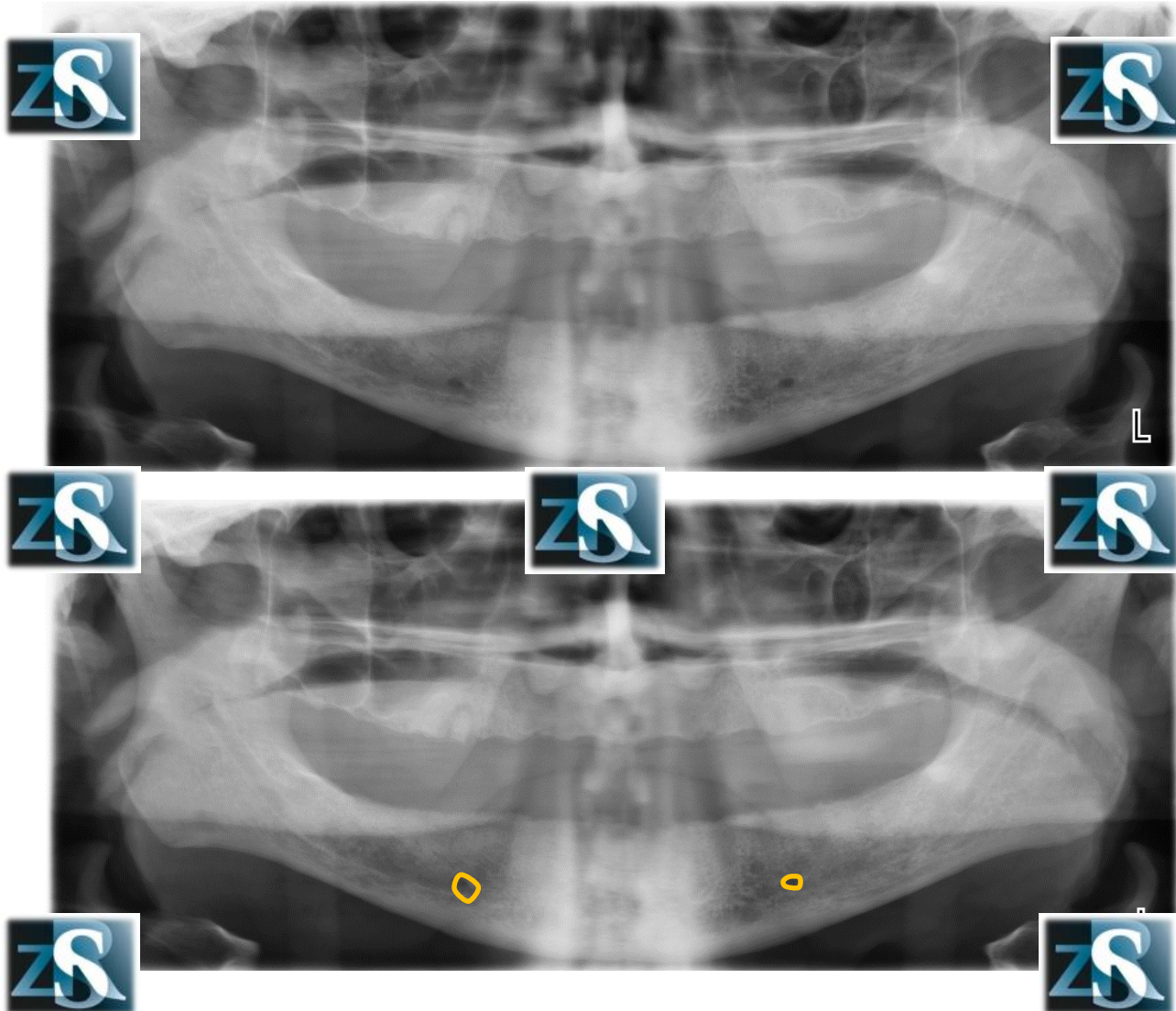
# Mandibular foramina



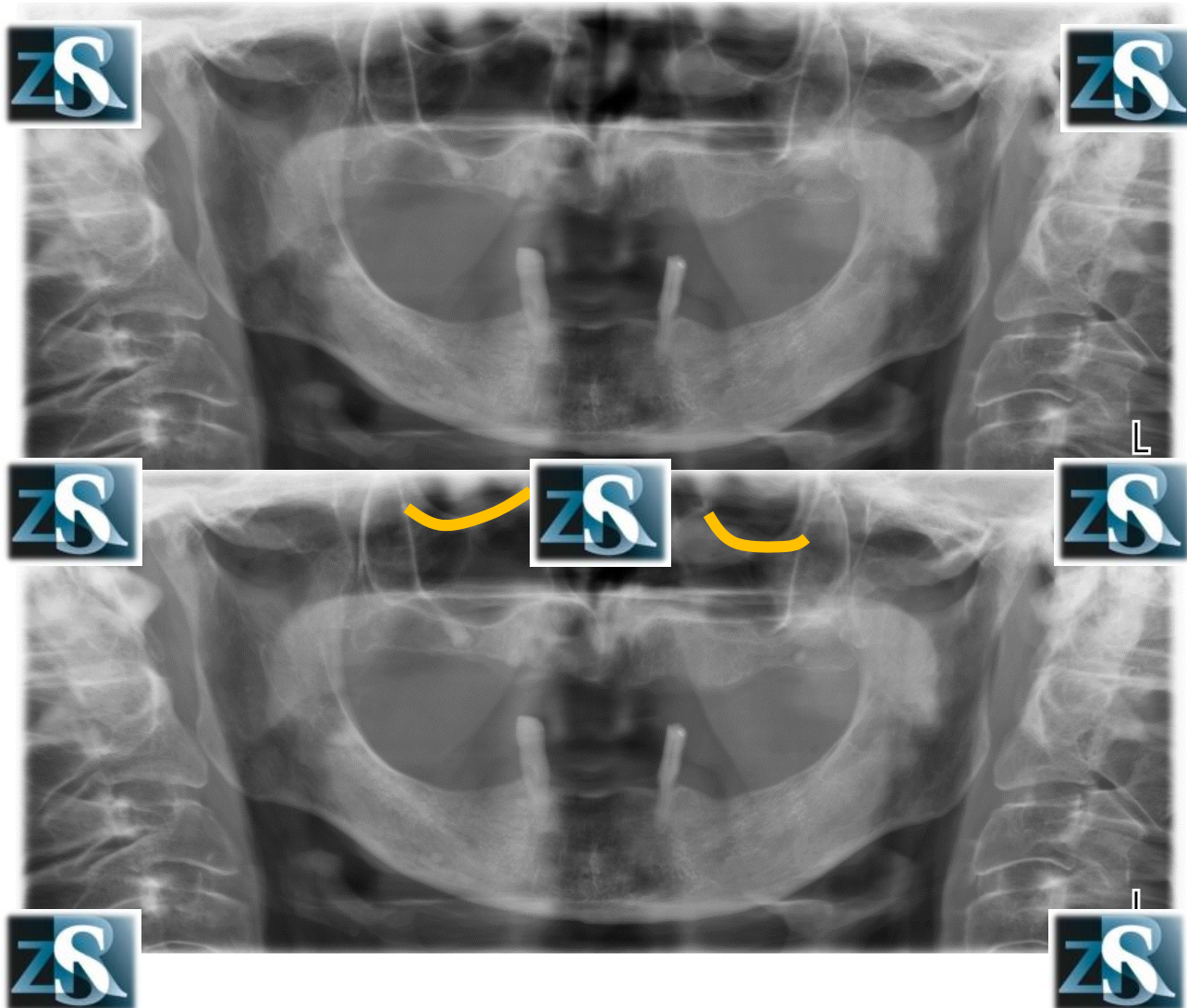
# Mandibular canals



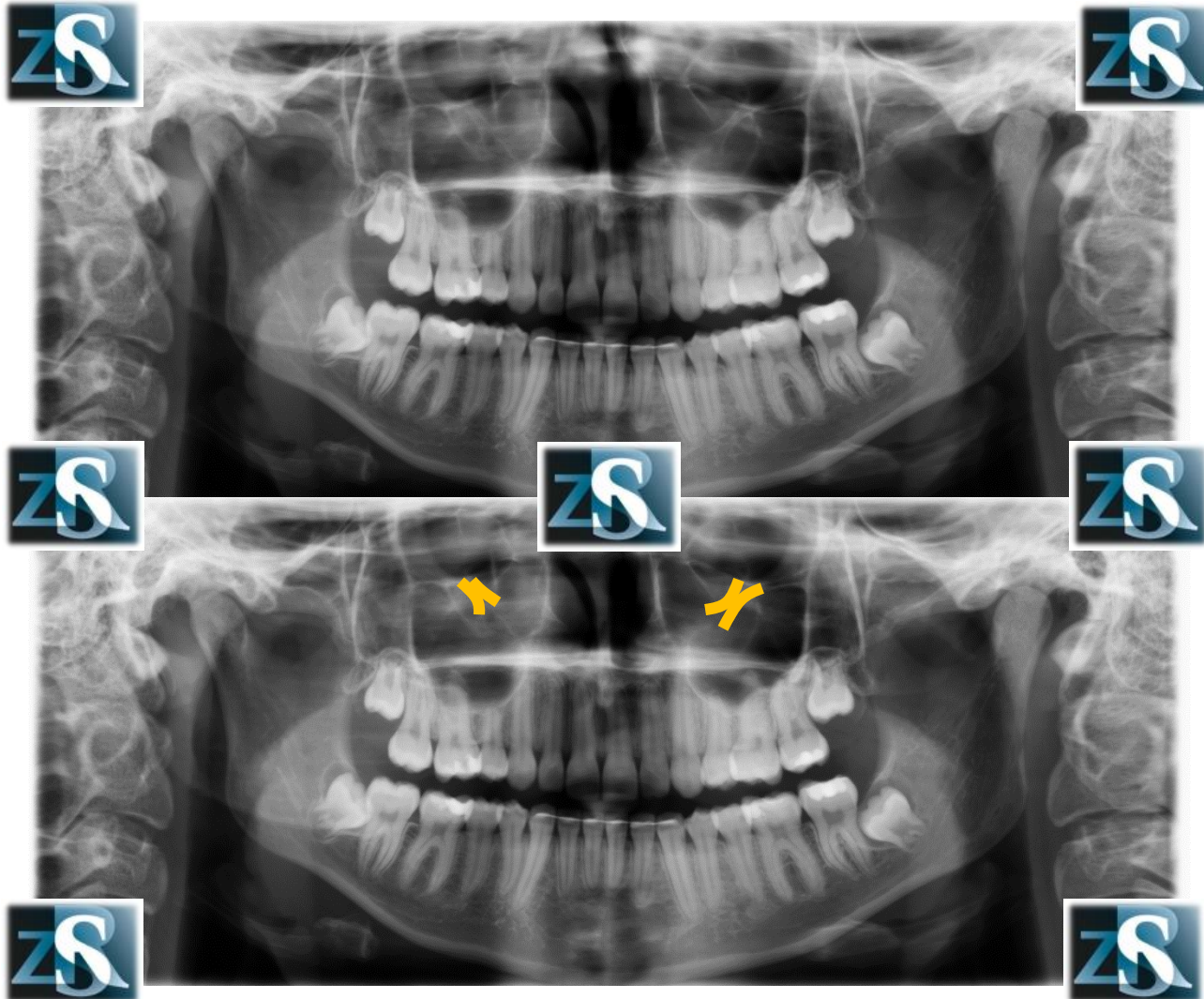
# Mental foramina



# The floor of the orbits

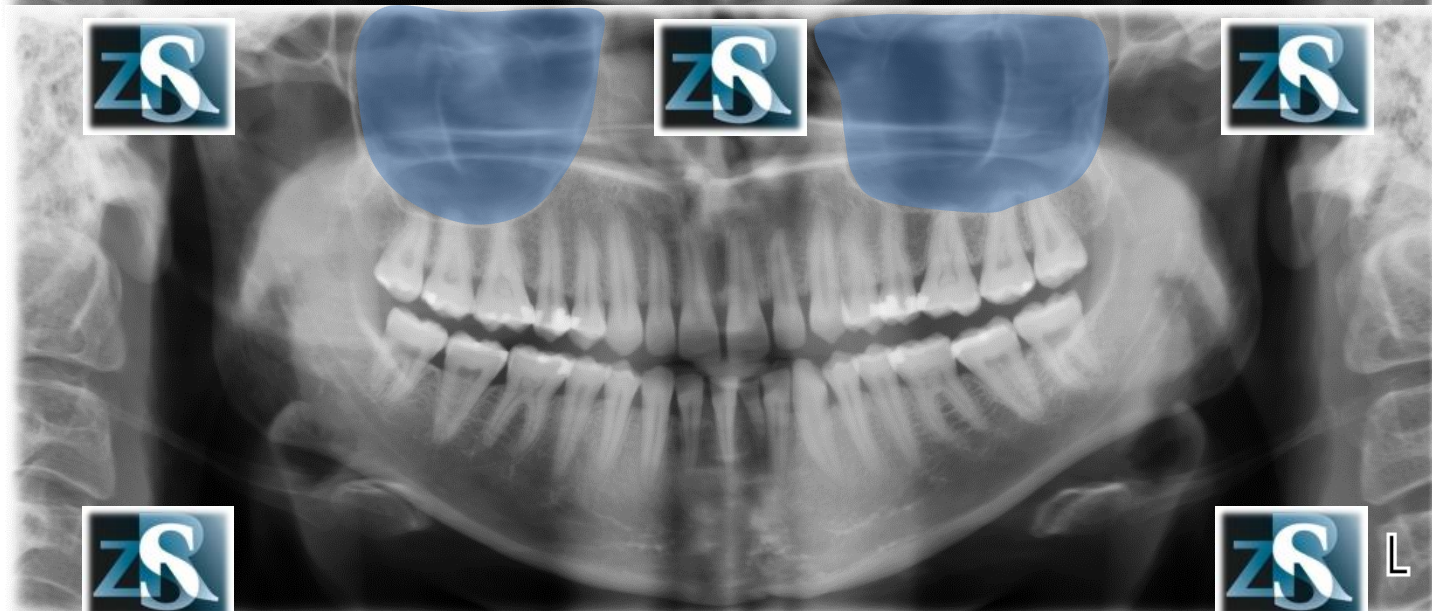
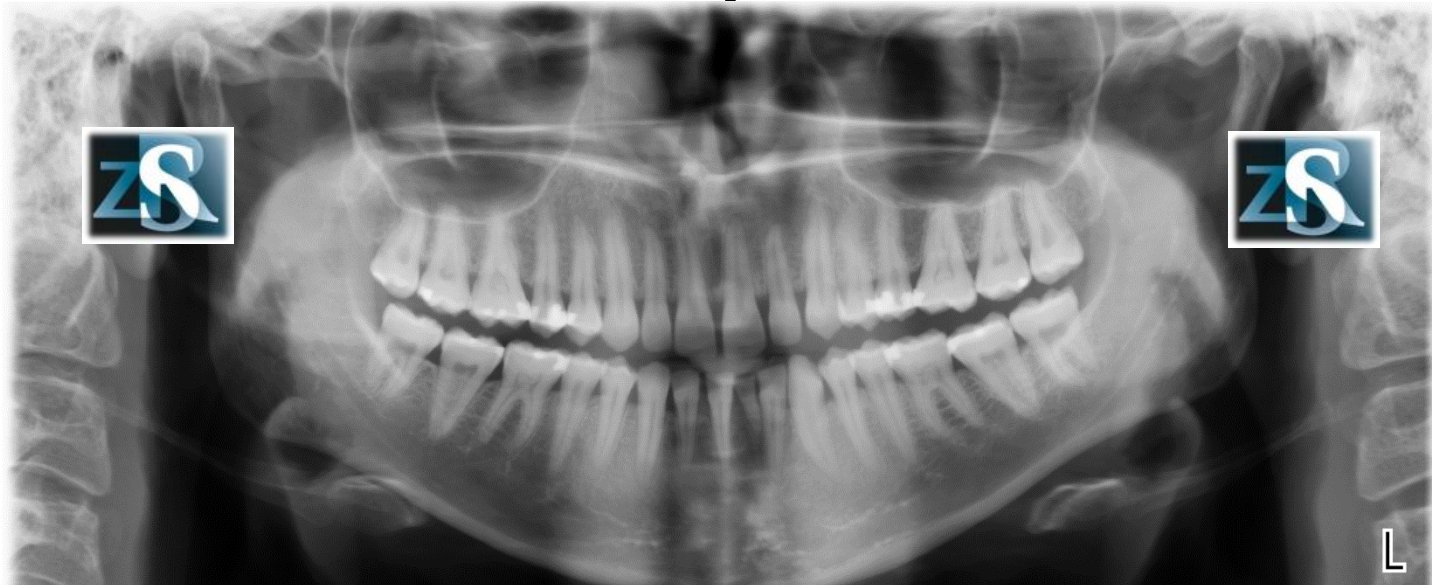


# Infraorbital canals

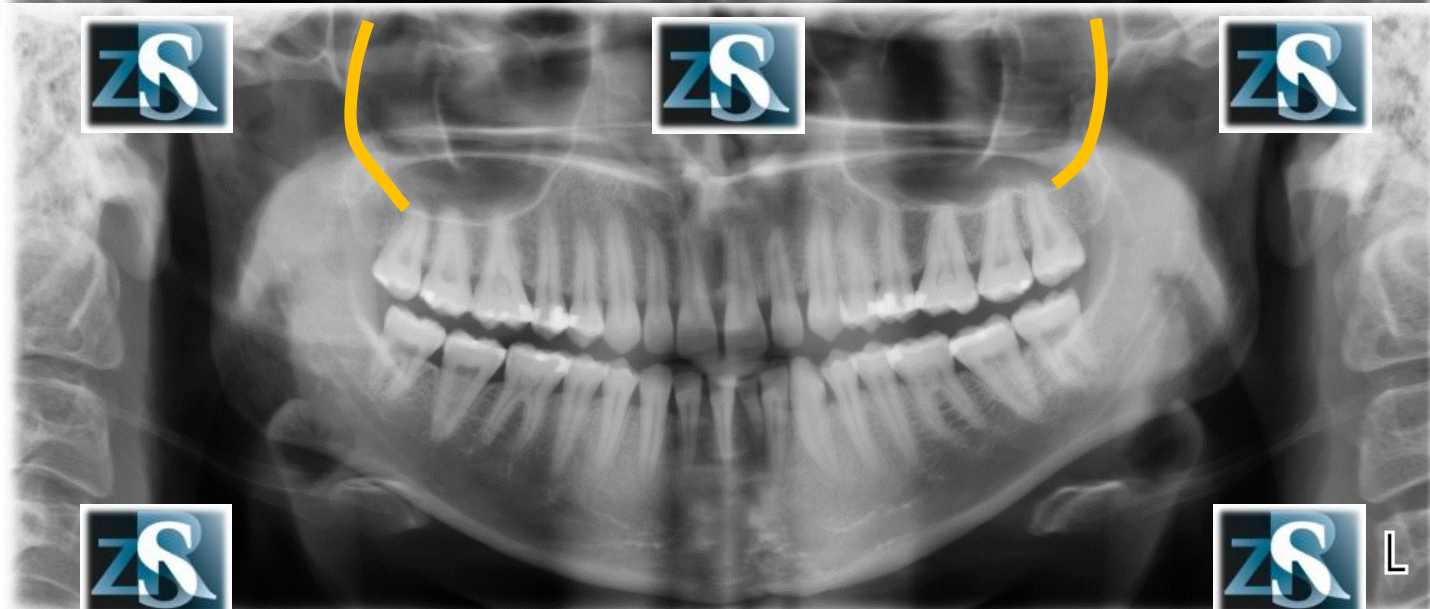
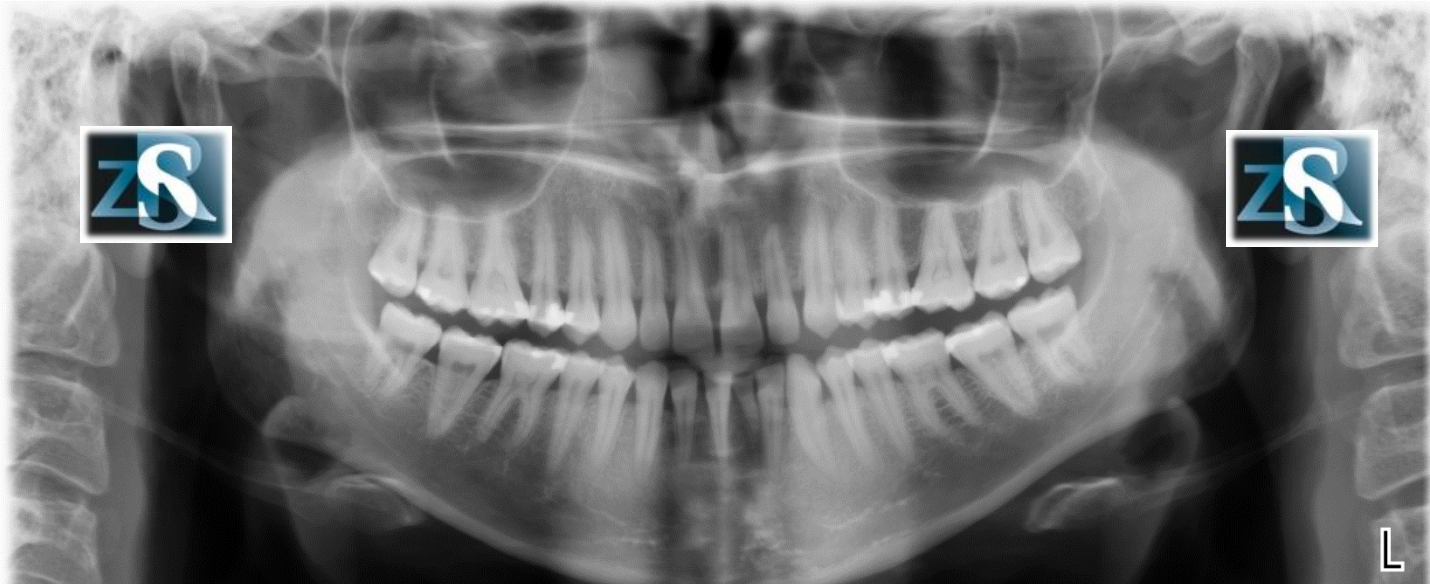




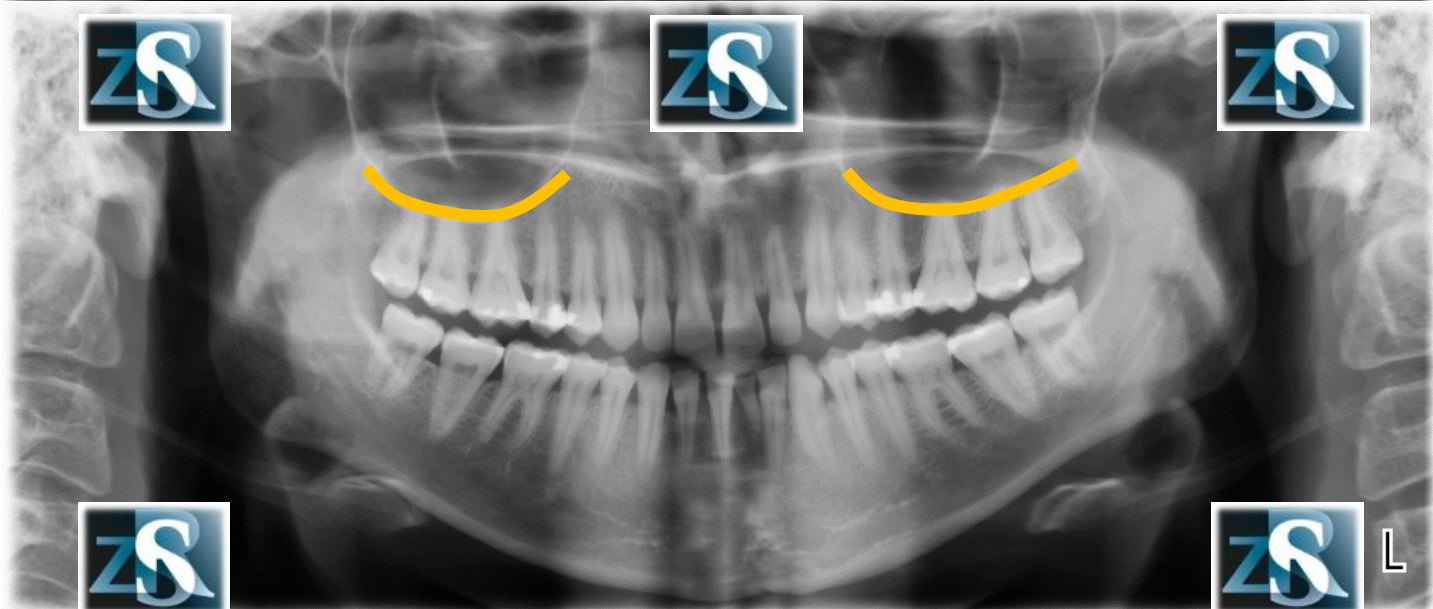
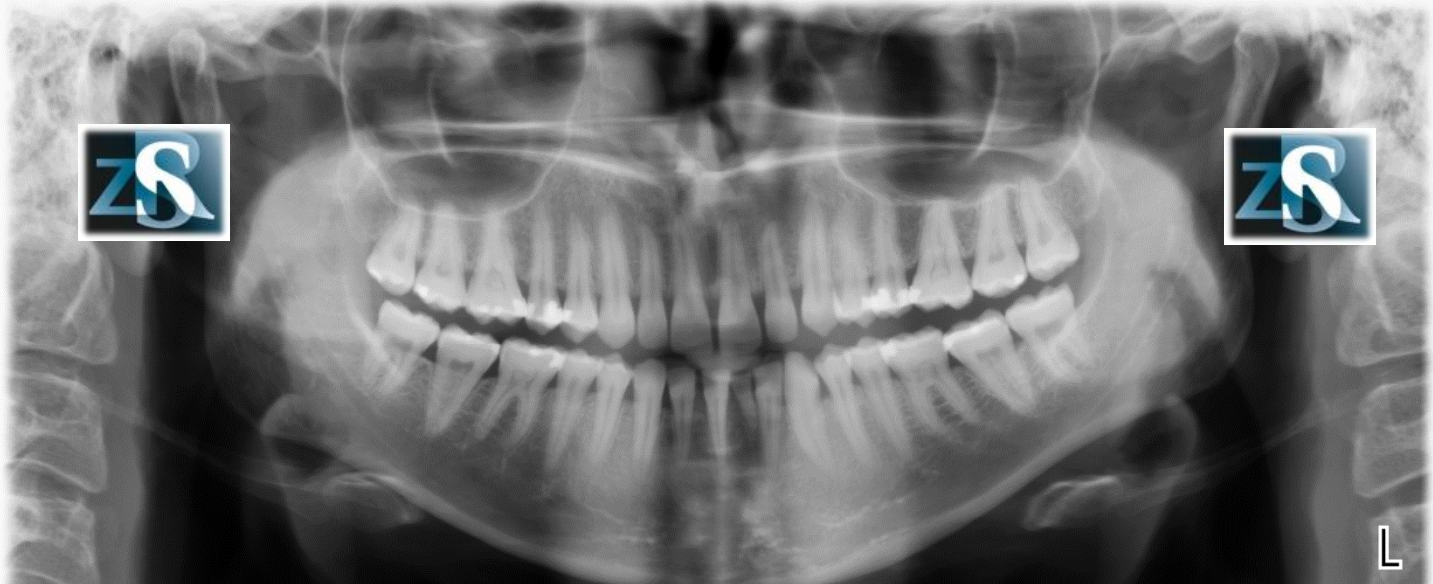
# Maxillary sinuses



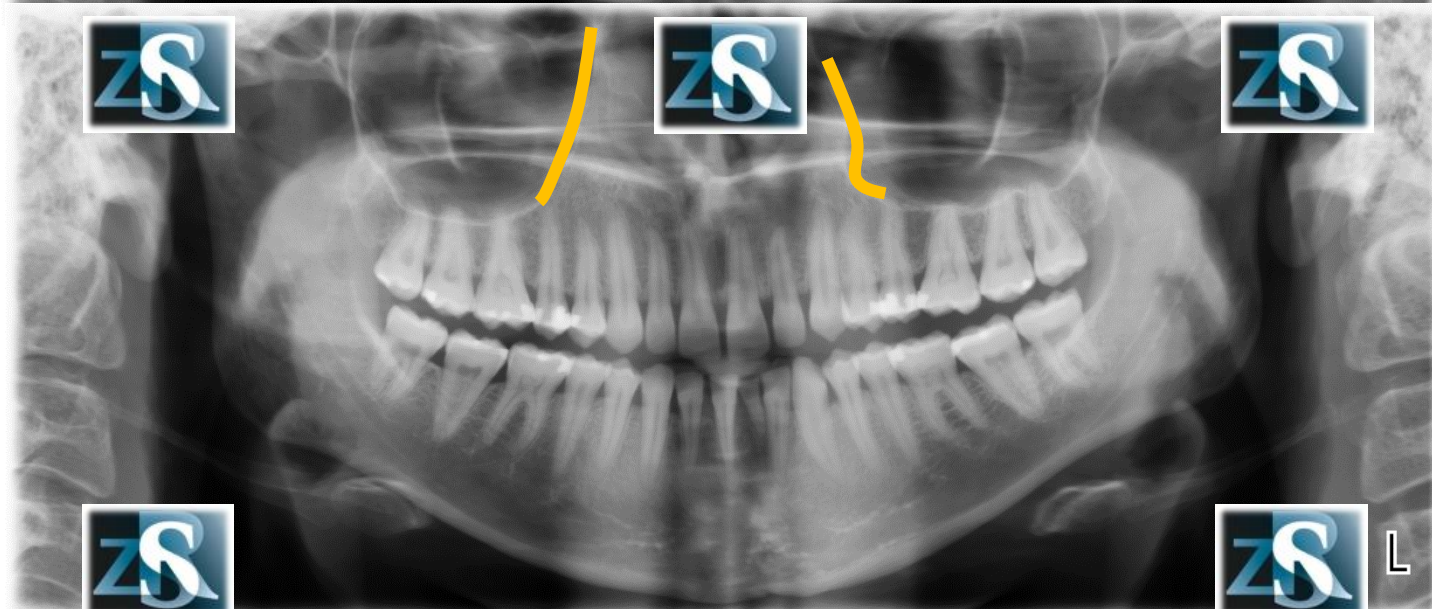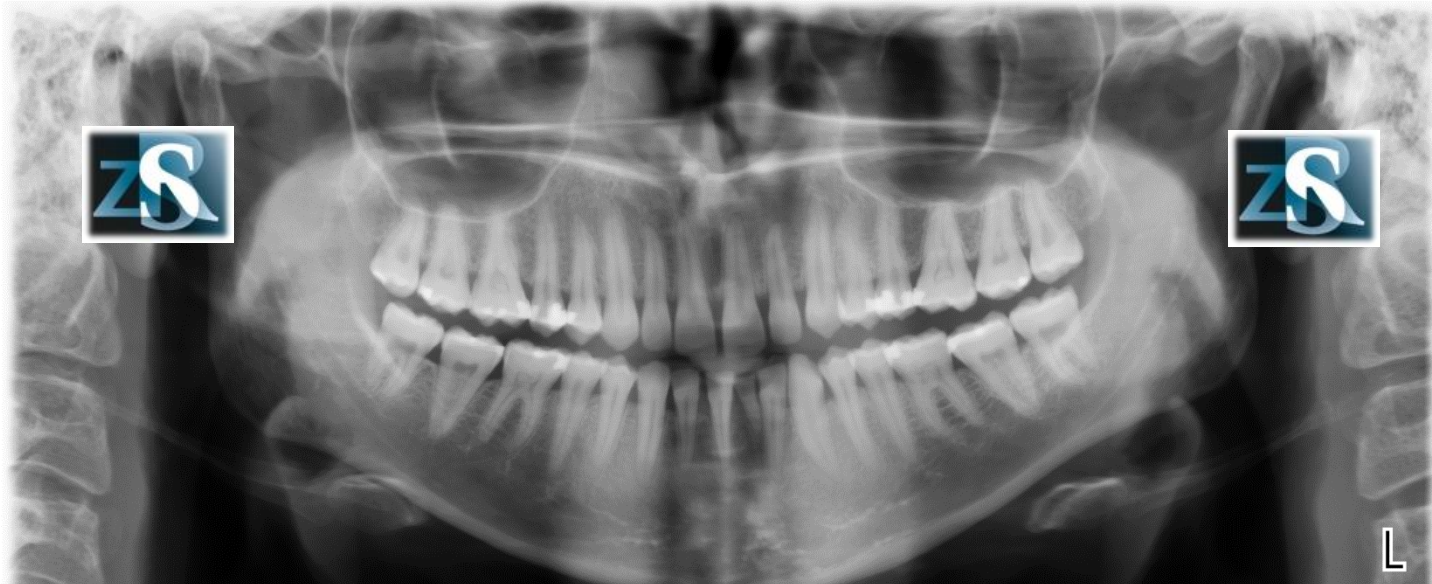
# Posterior walls of the maxillary sinuses



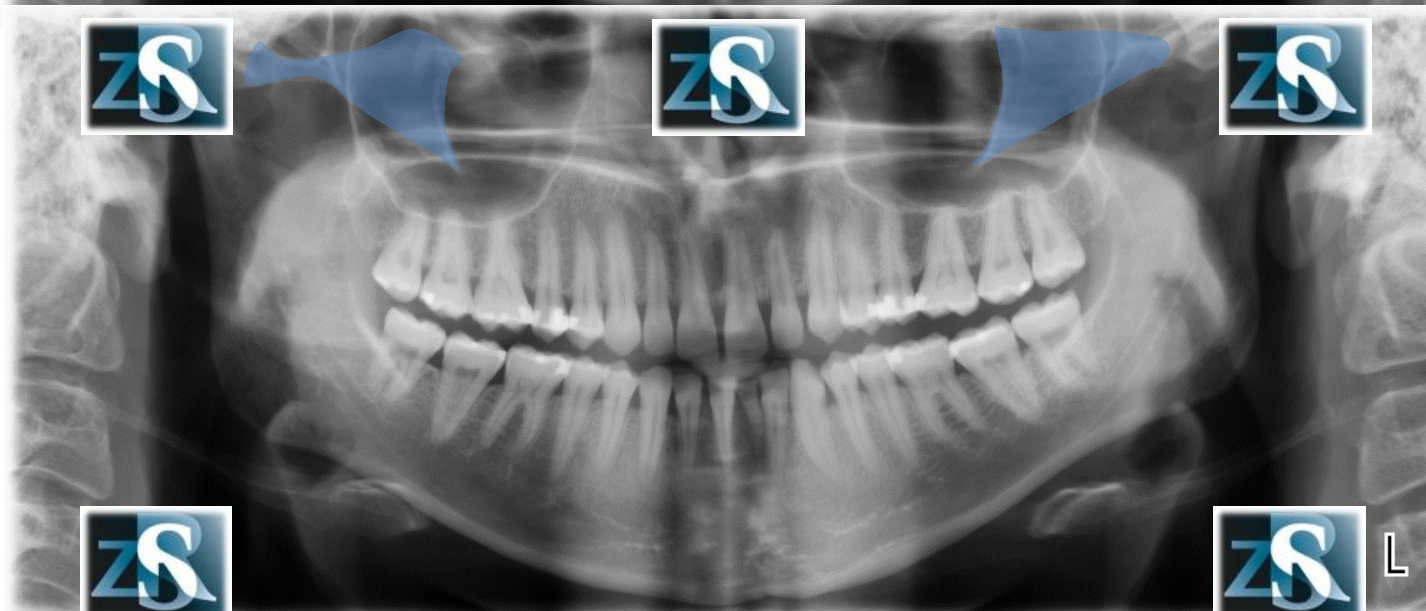
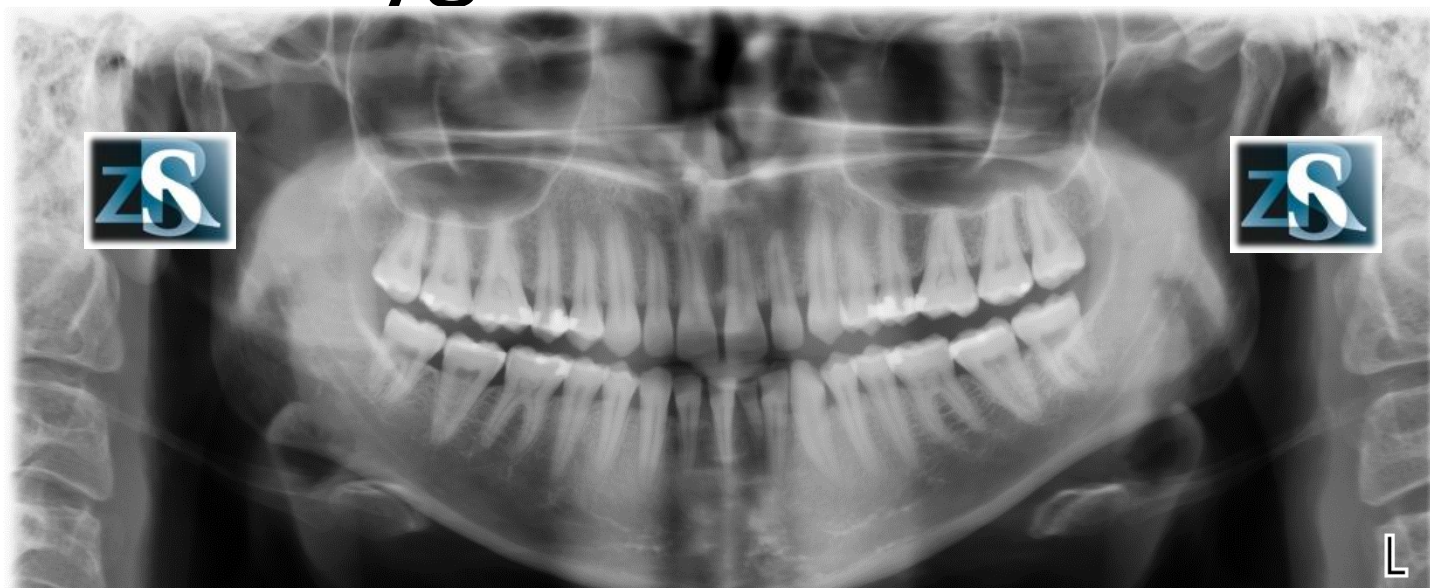# The floor of the maxillary sinuses



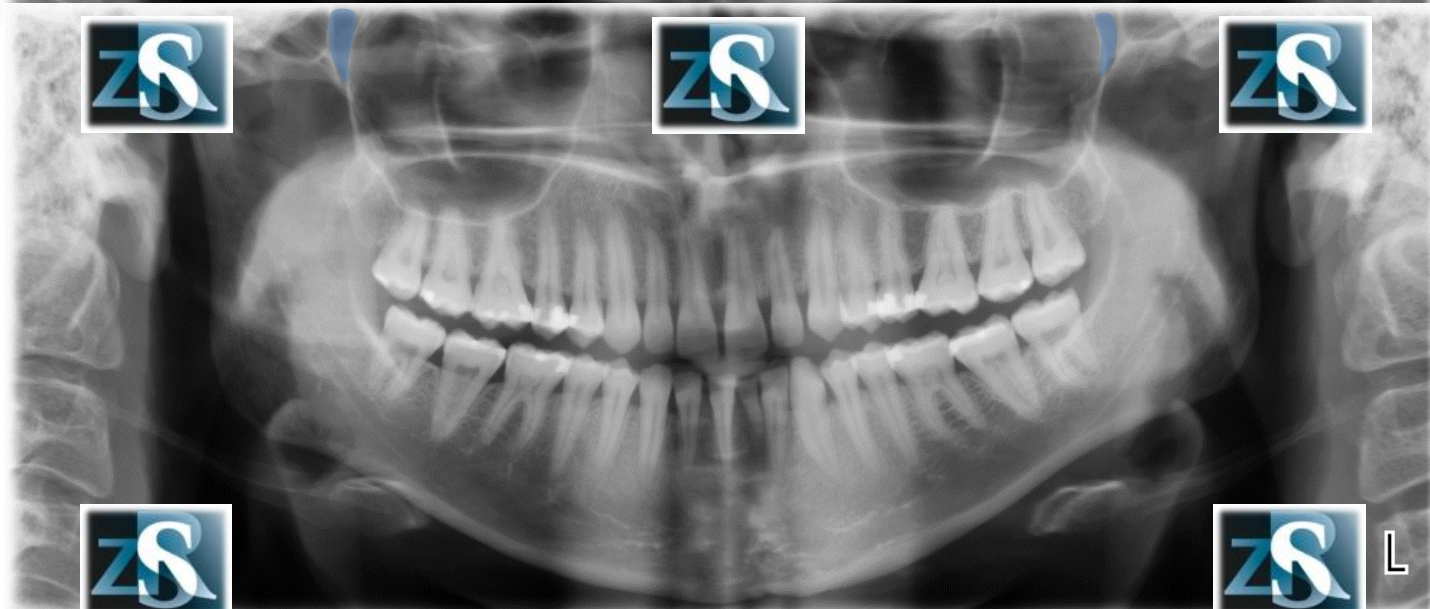
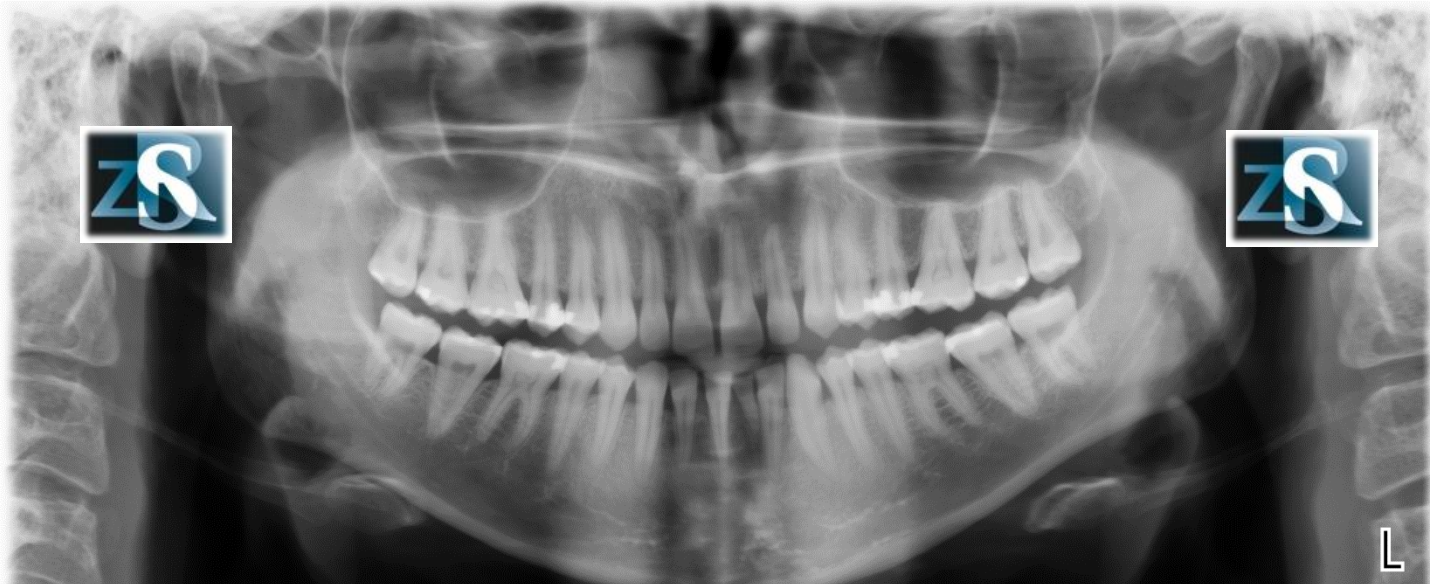
# Medial wall of the maxillary sinuses



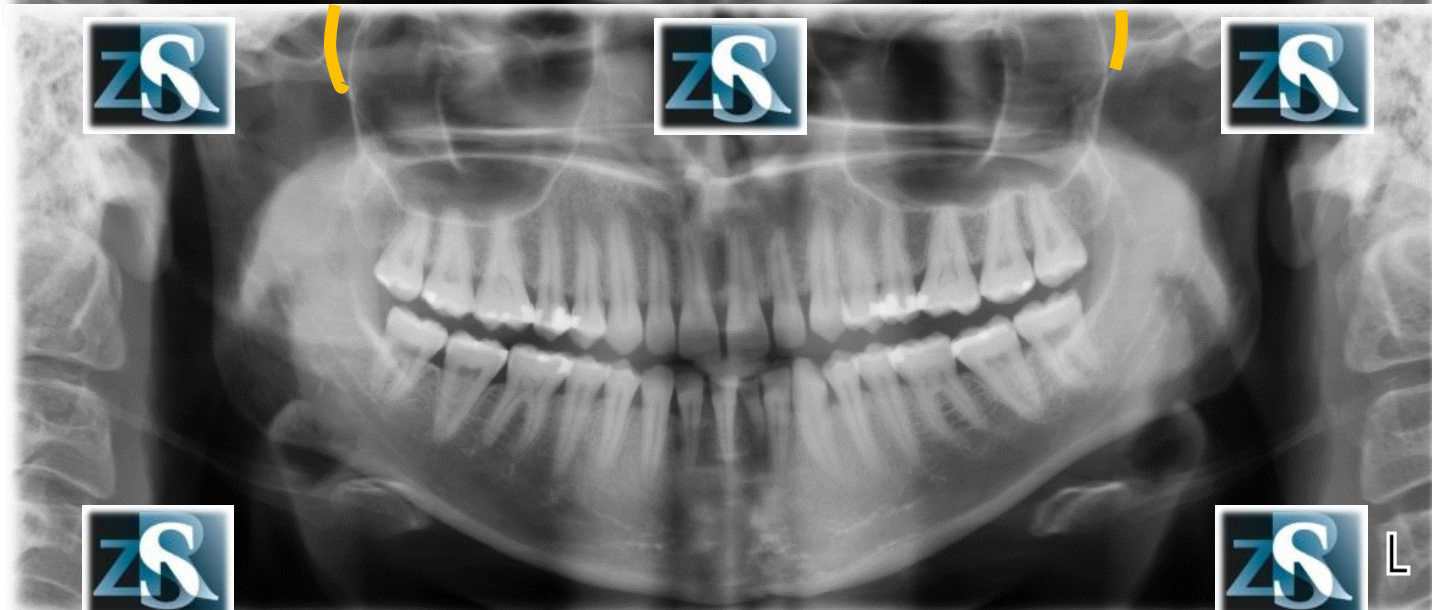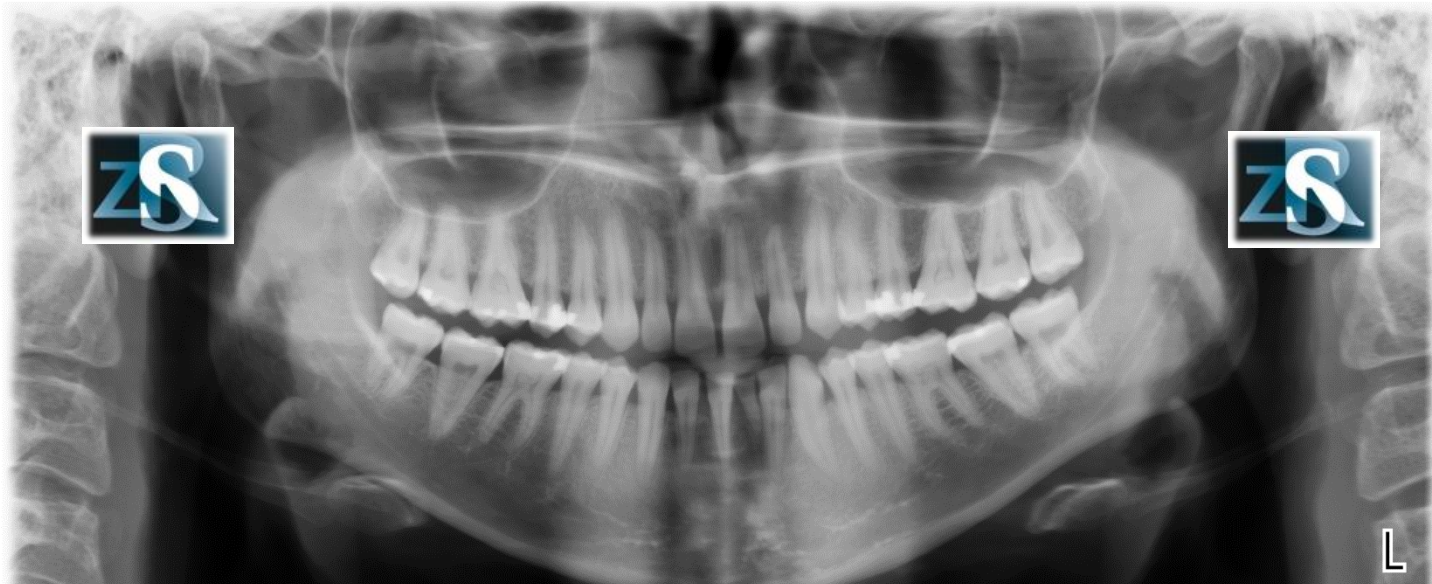
# Zygomatic arches



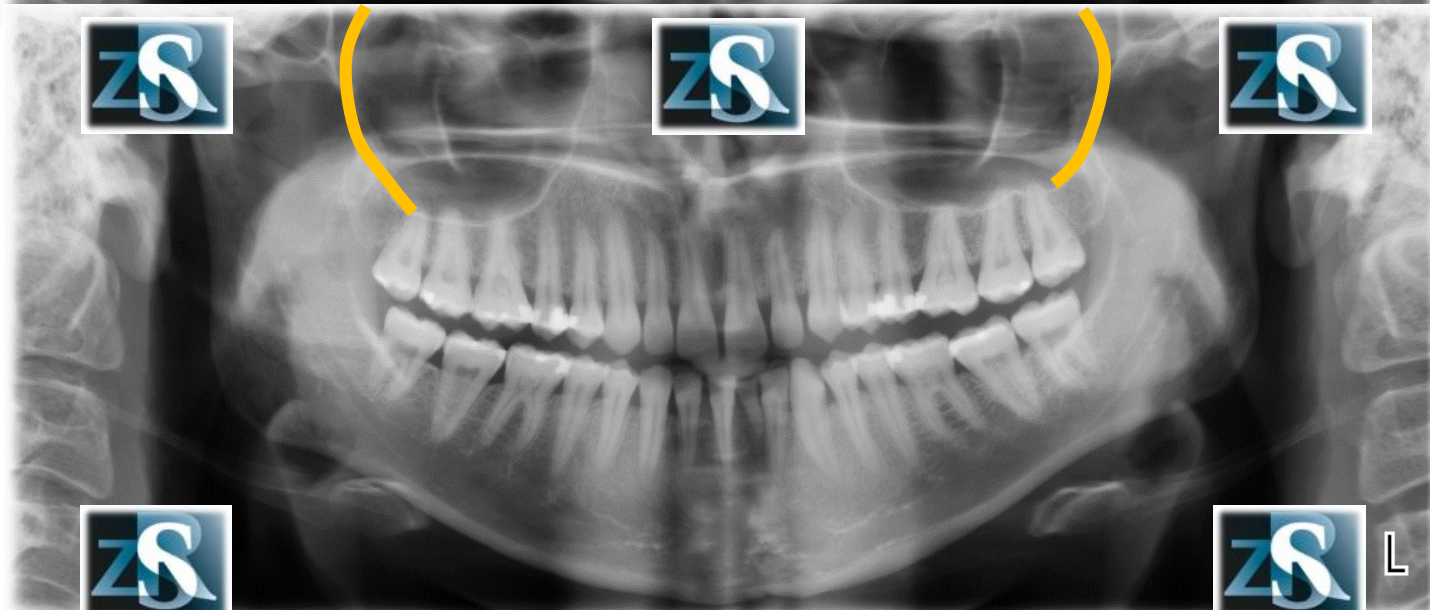
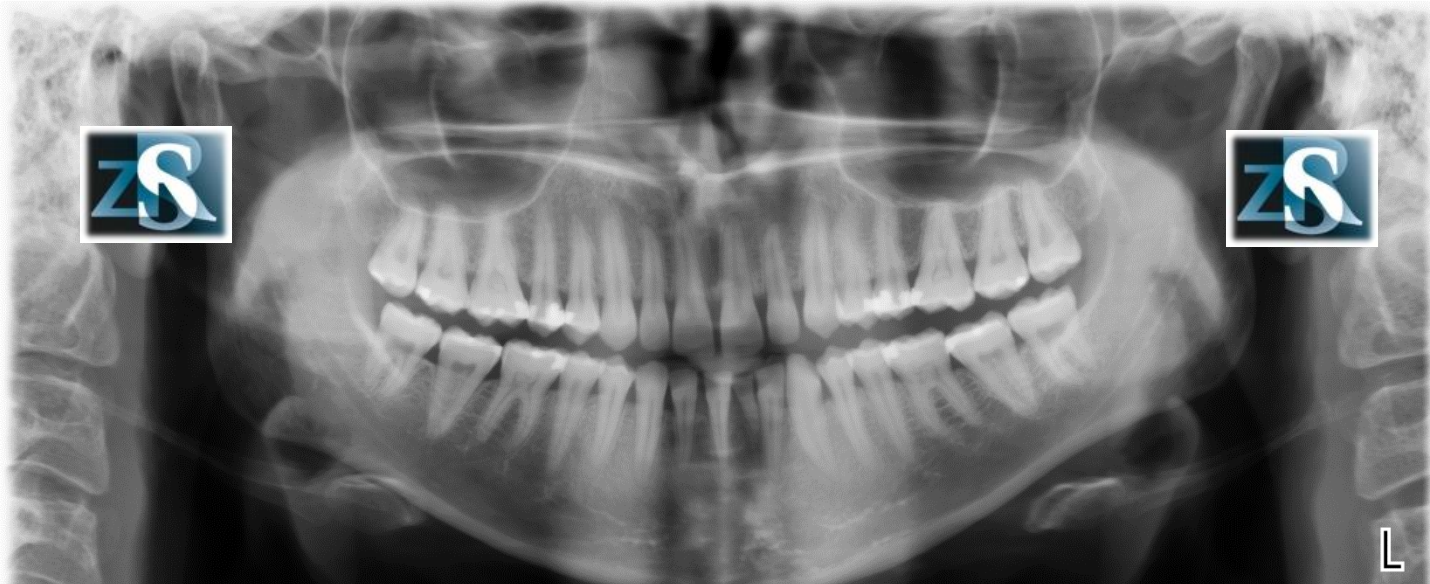
# Pterygomaxillary fissure (fossa)



# Lateral pterygoid plate

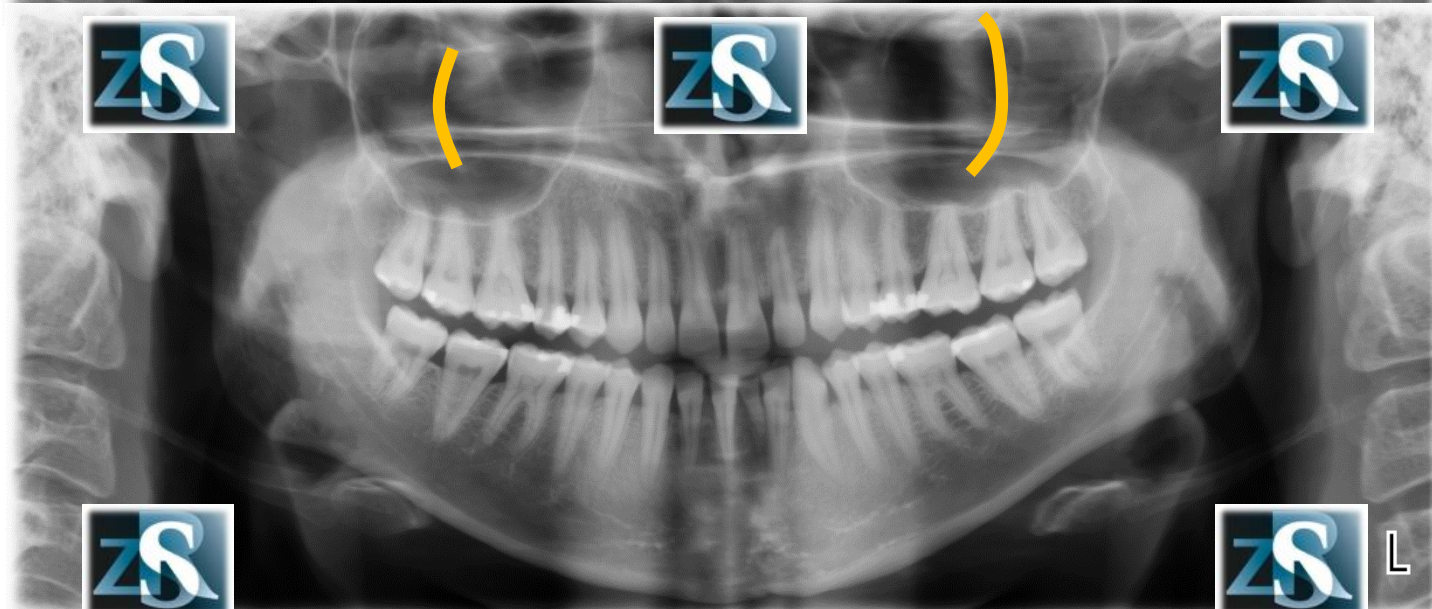
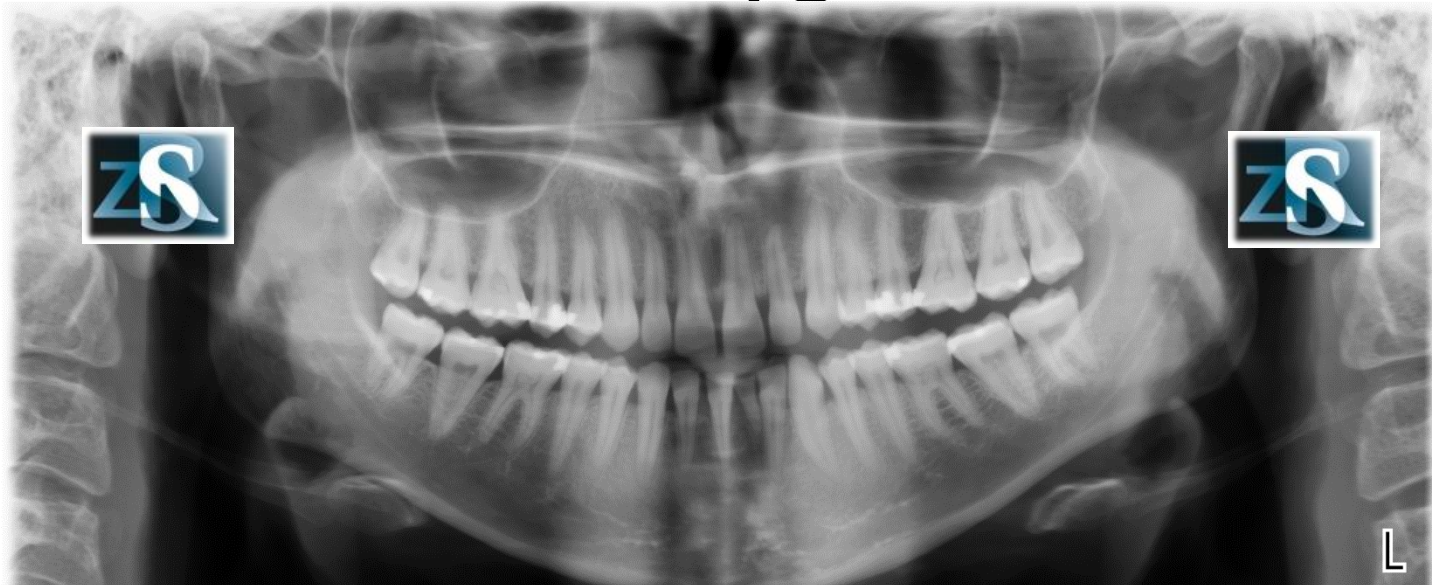


# Posterior walls of the maxillary sinuses

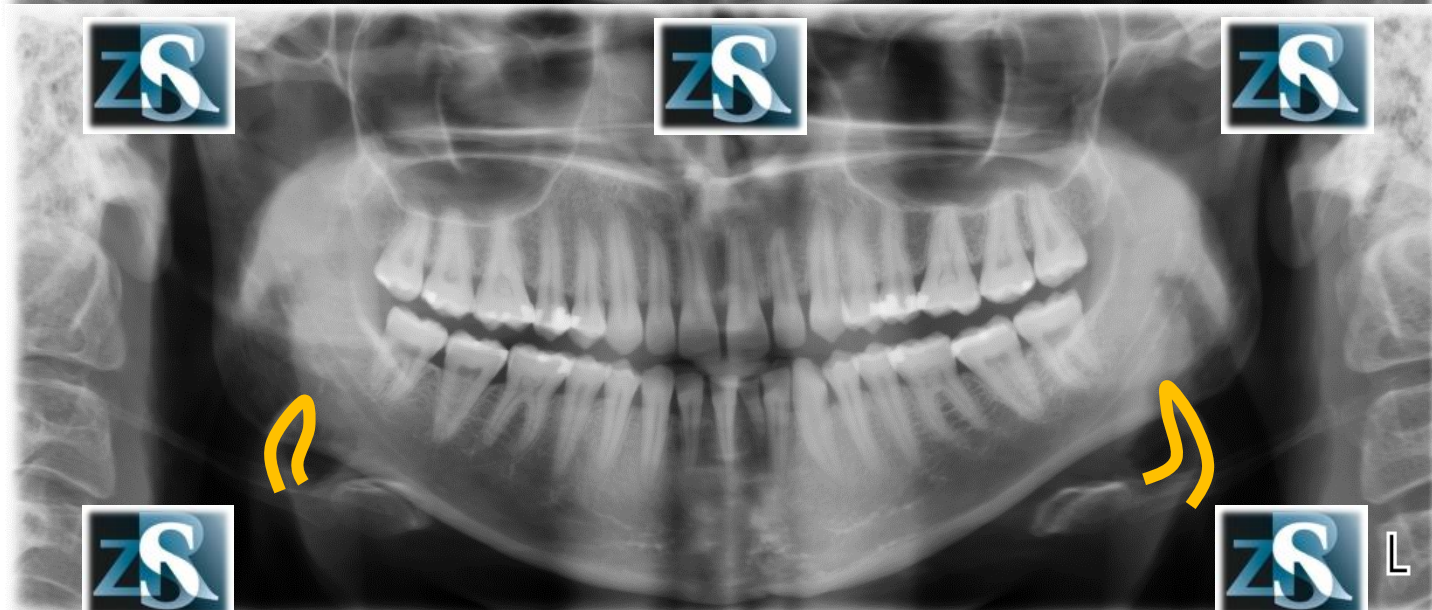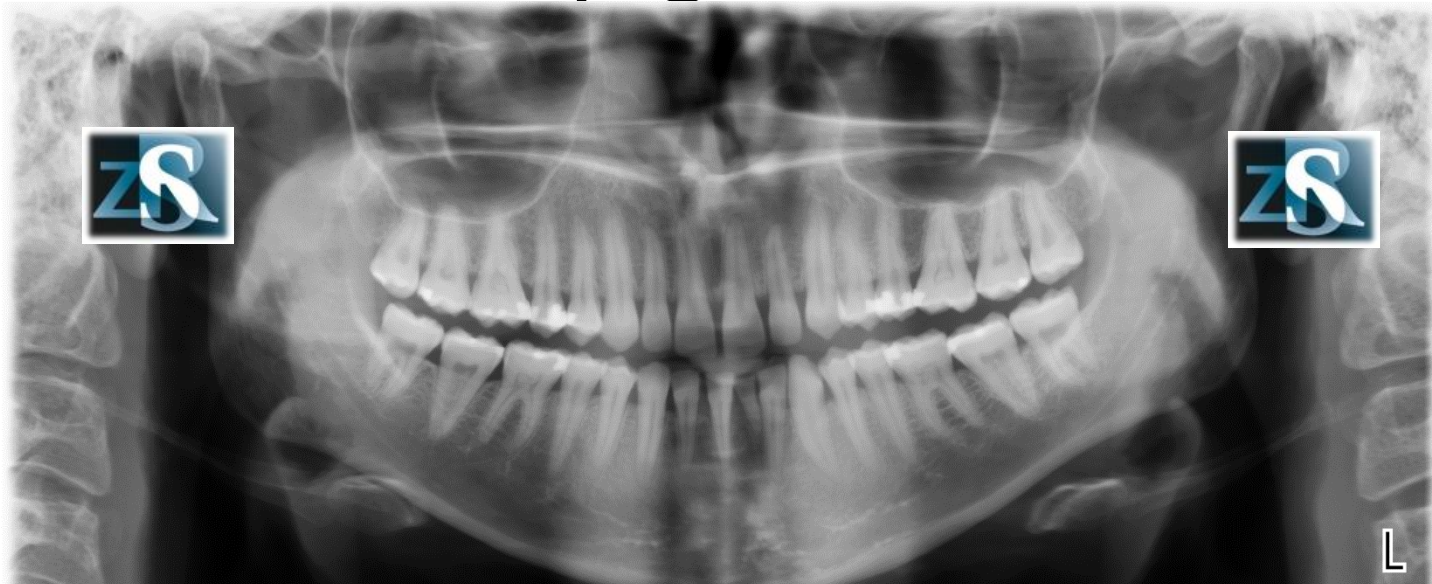




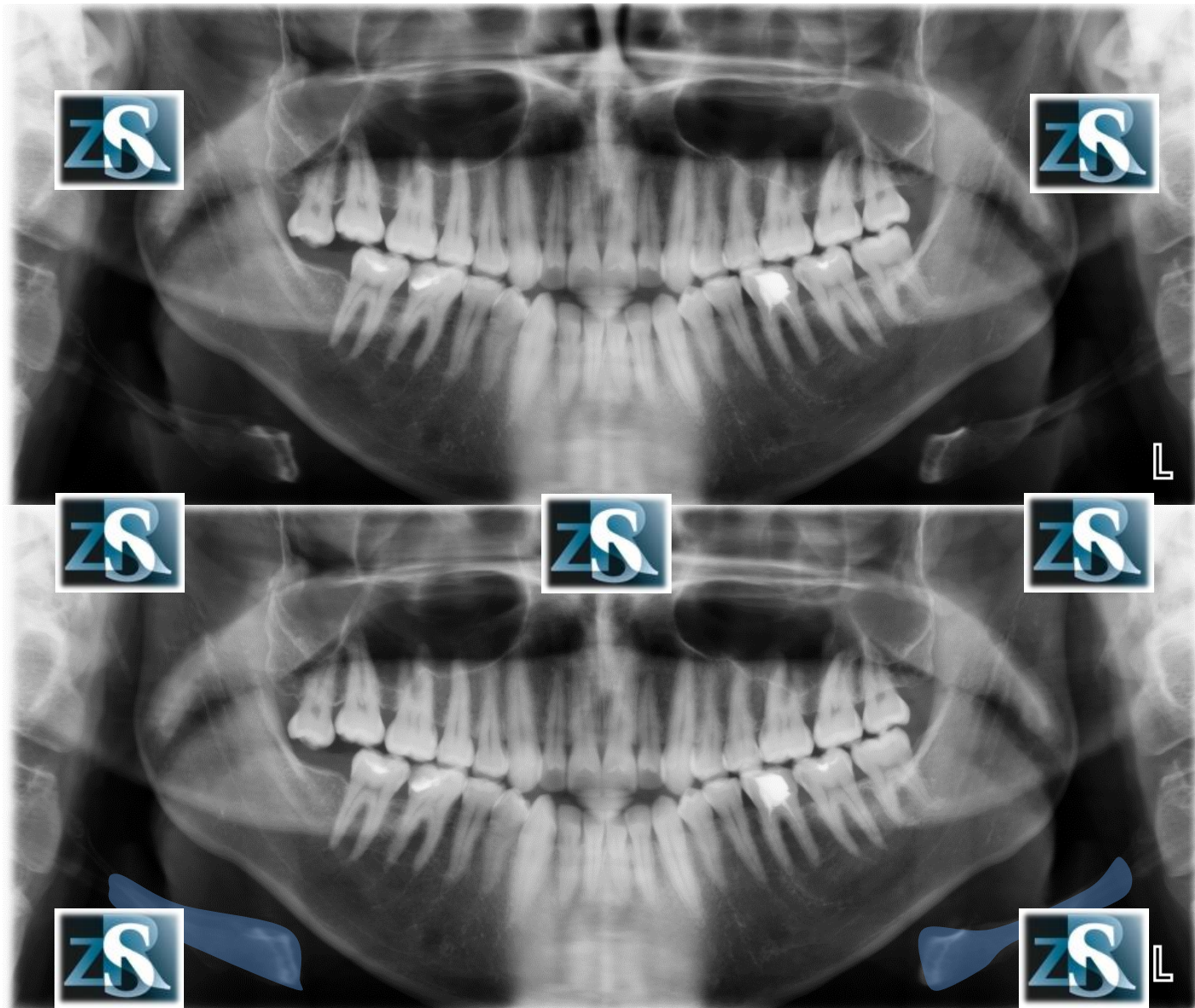
# Border of the zygomatic bone



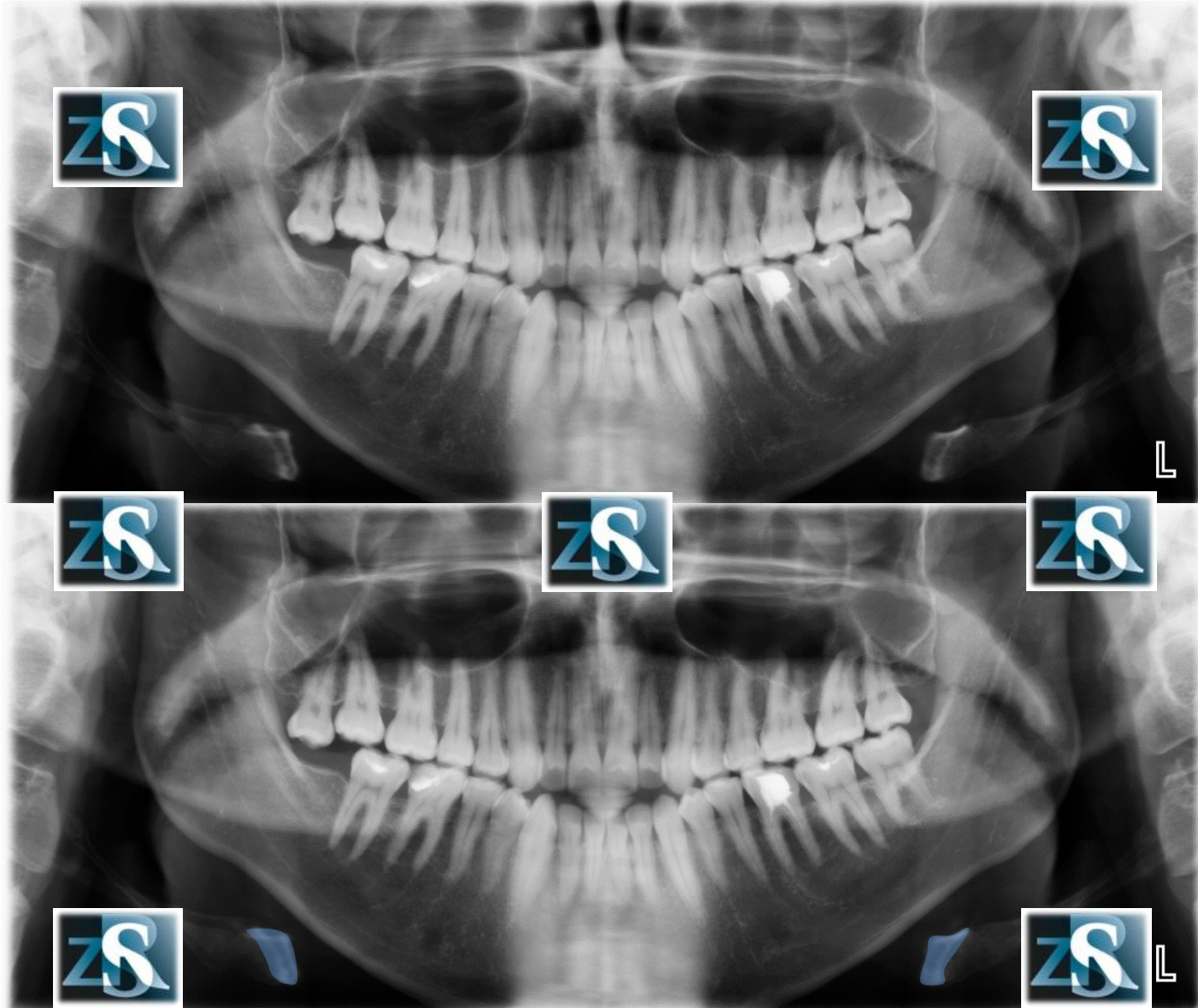
# Epiglottitis



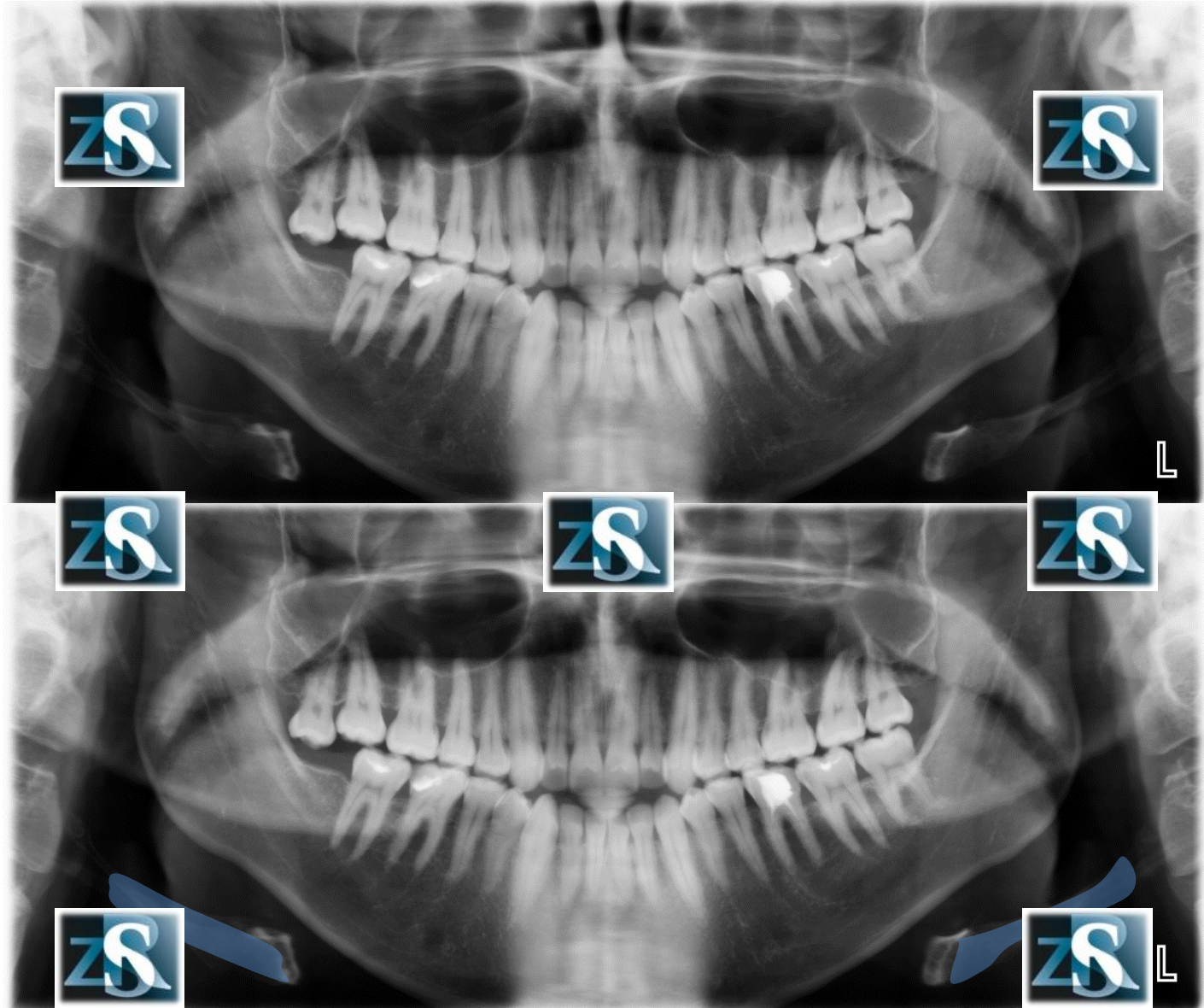
# Hyoid bone



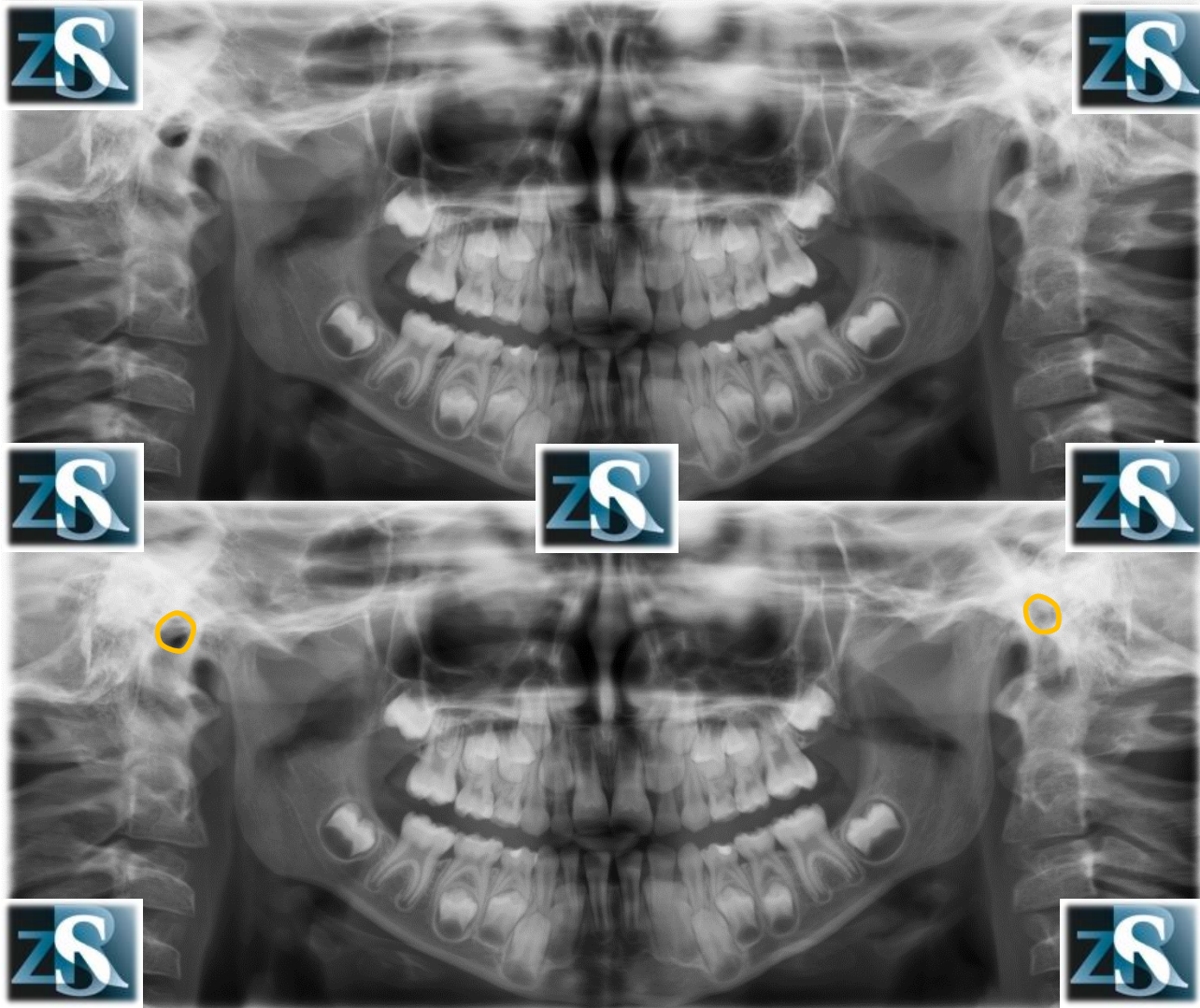
# Hyoid bone – body, lesser cornua



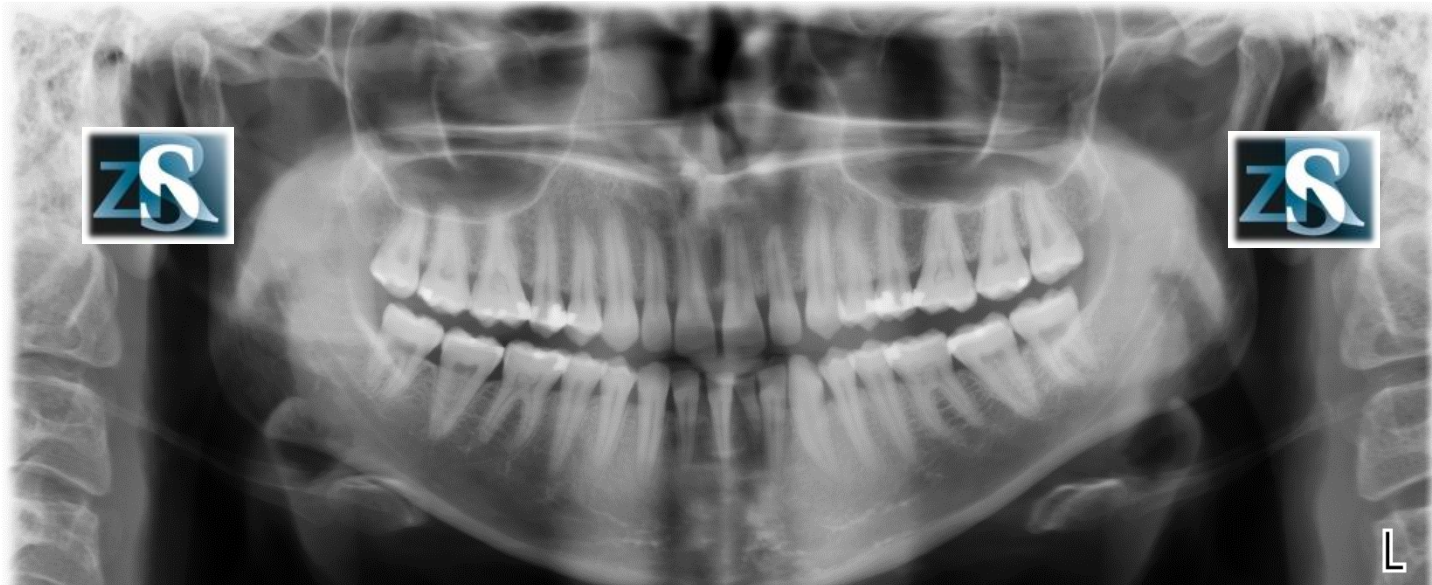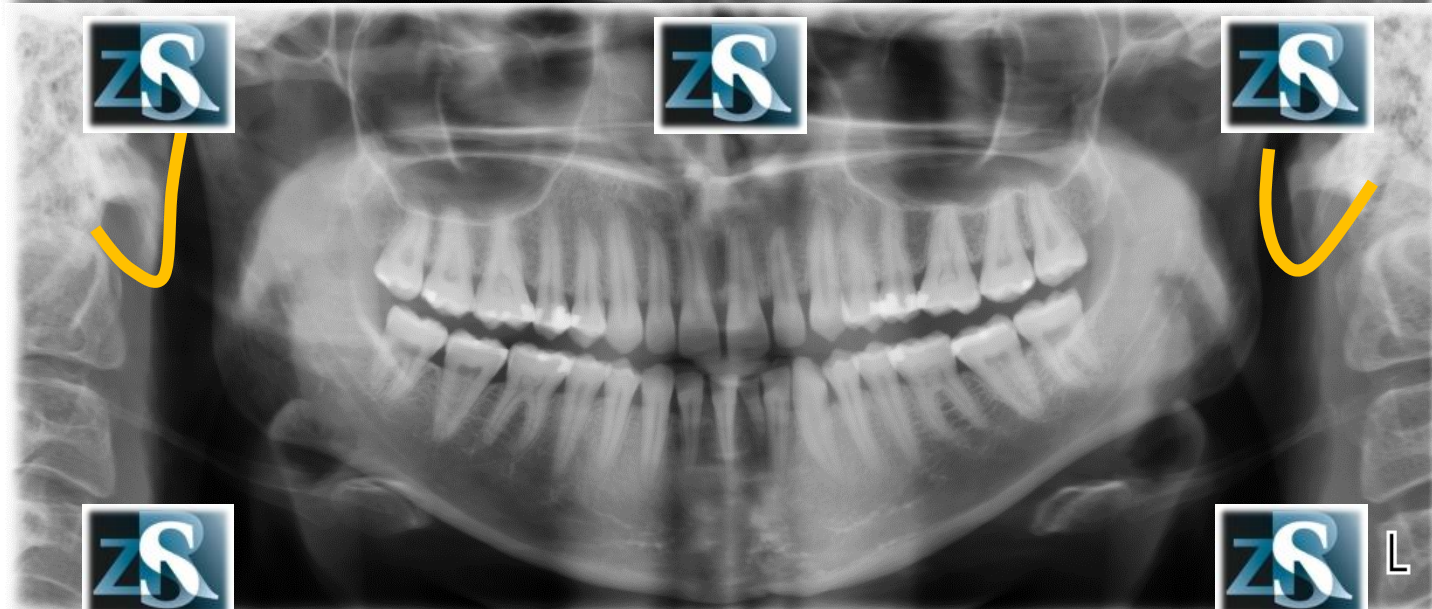
# Hyoid bone – major cornua



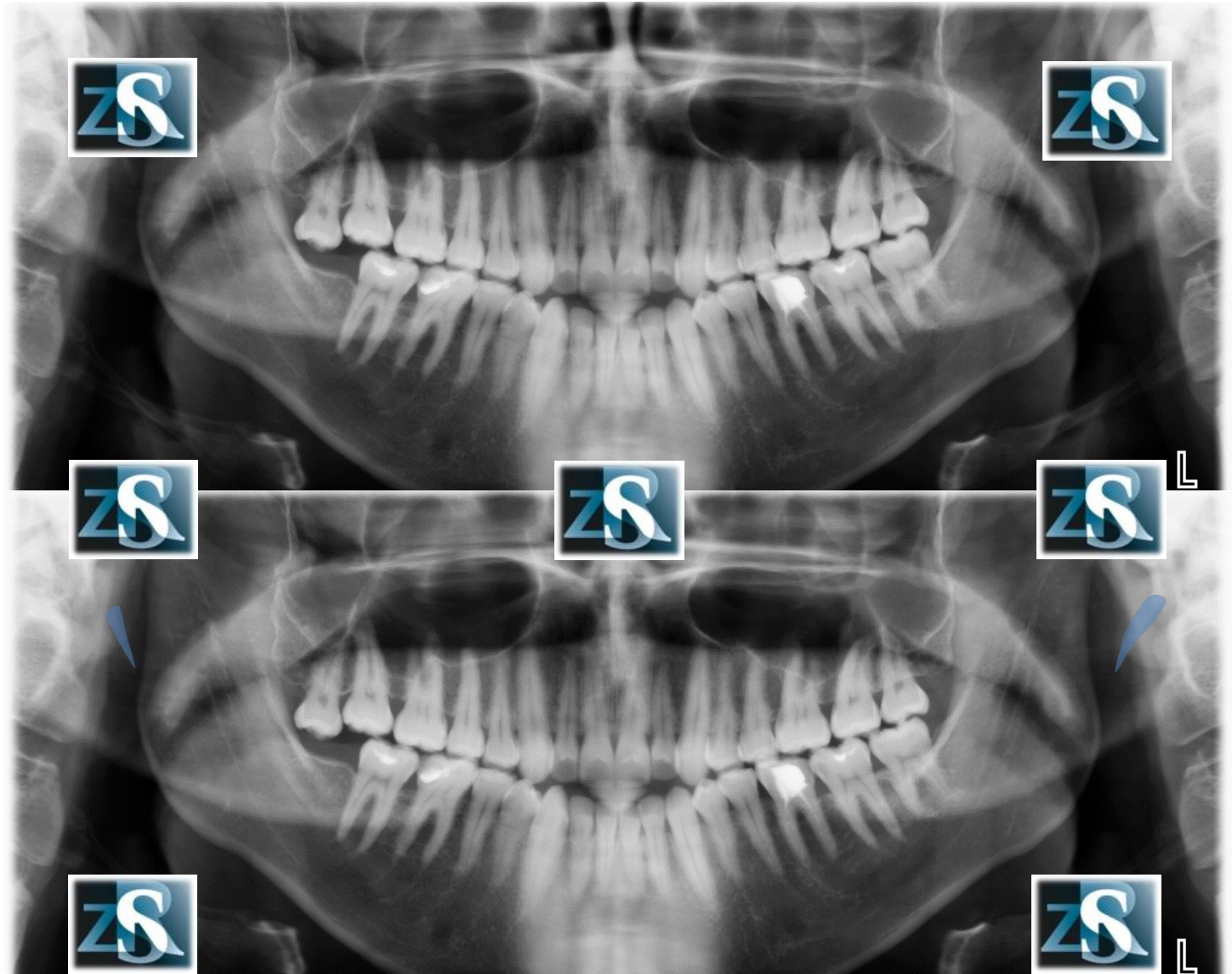# External auditory meatus



# Earlobes

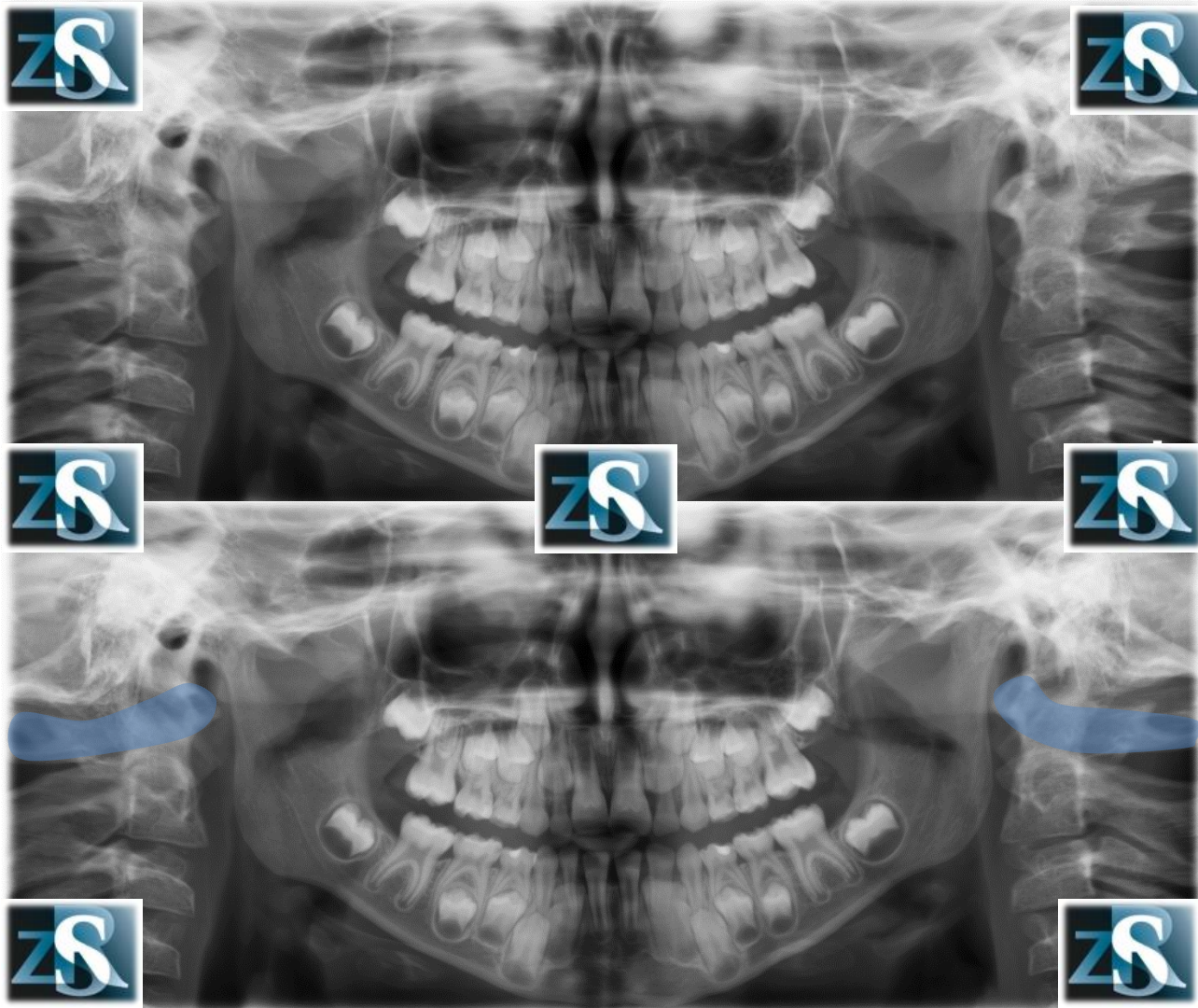


# Styloid process, calcified stylo-mandibular and/or stylohyoid ligament

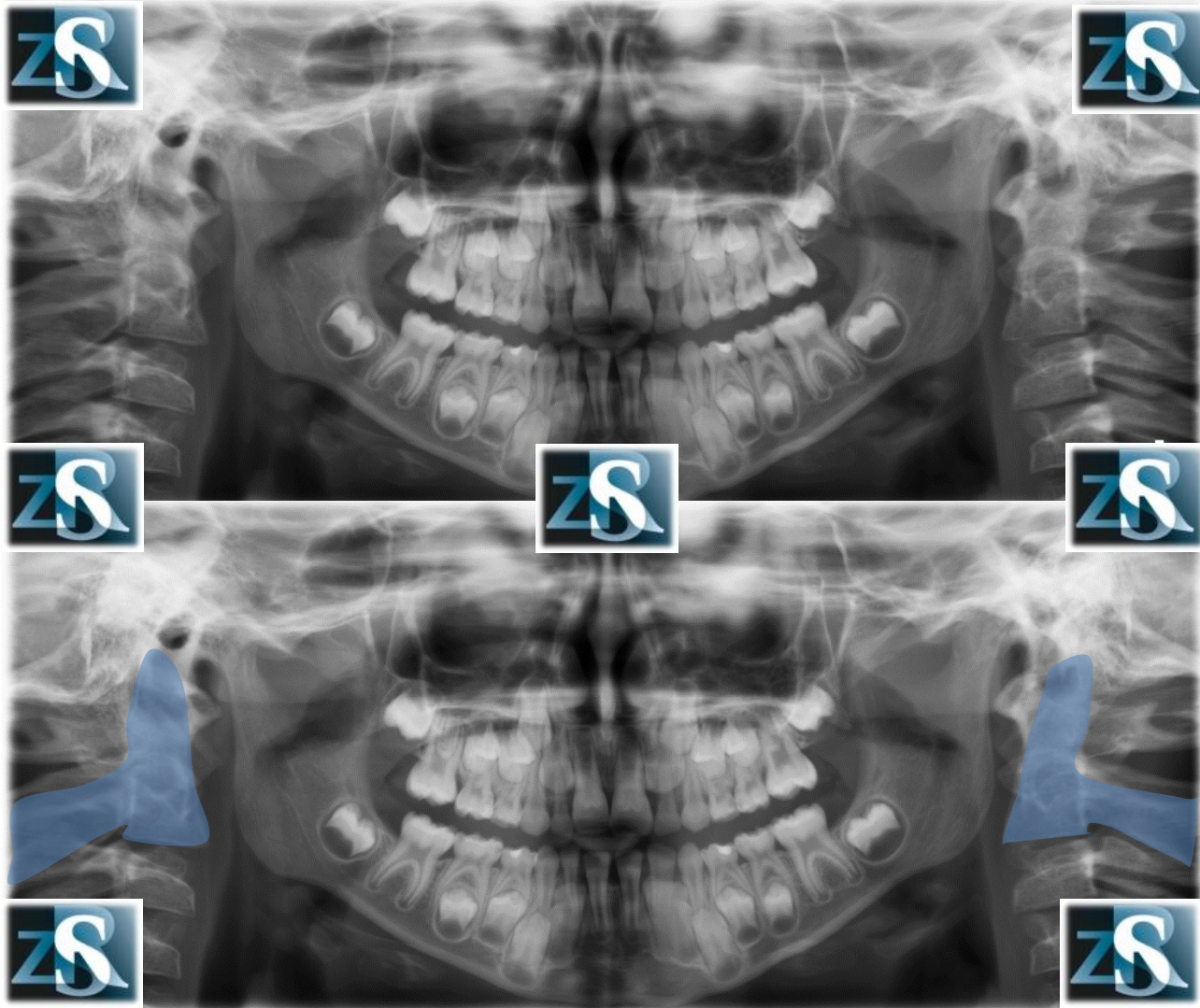




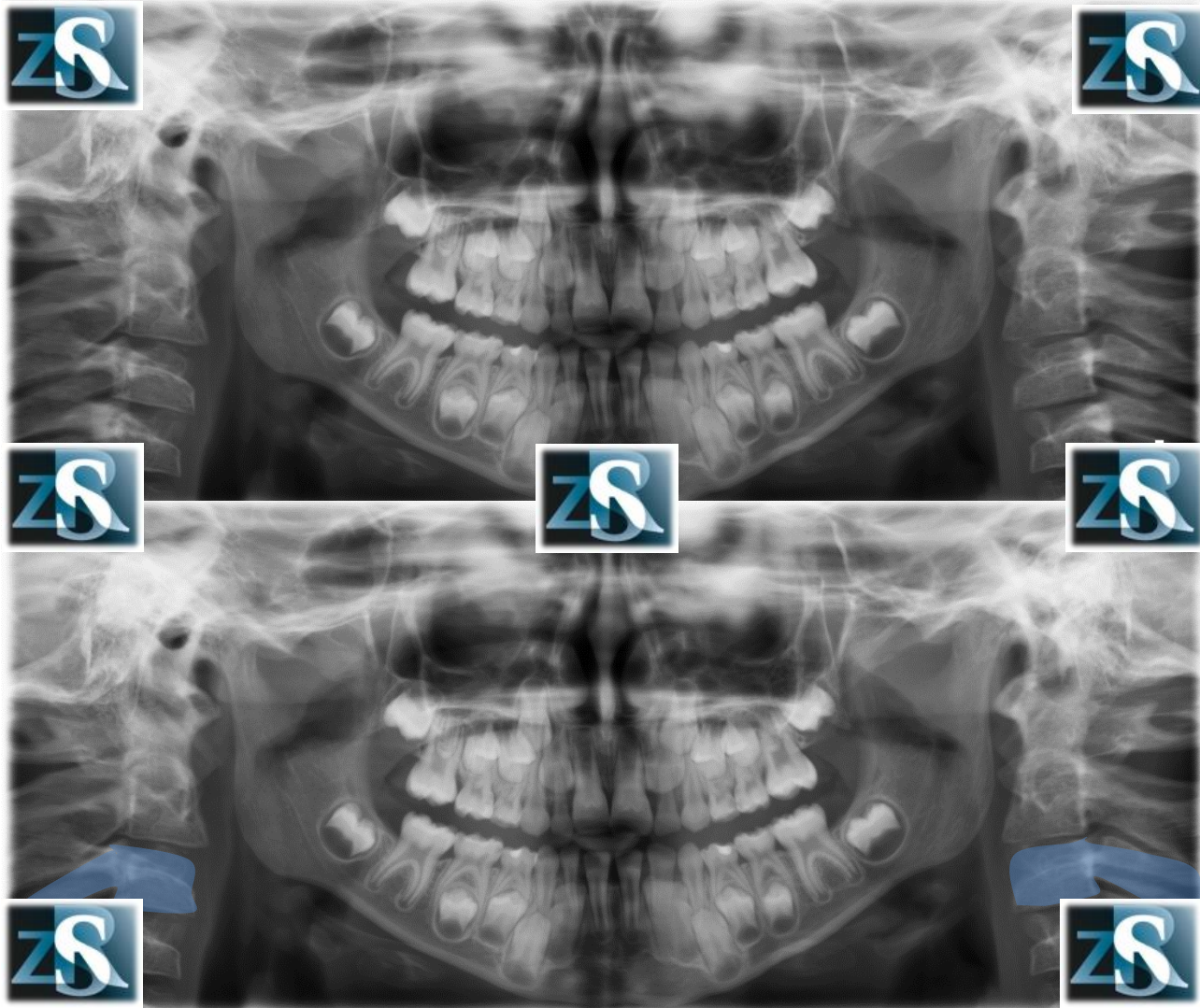
# Cervical spine (C1, atlas)



# Cervical spine (C2, axis)



# Cervical spine (C3)



# Cervical spine (C4)

